

CASE REPORT

Evaluating long-latency auditory evoked potentials in the diagnosis of cortical hearing loss in children

Teresa Lopez-Soto^{1,*}, Amparo Postigo-Madueno², and Pedro Nunez-Abades³¹Department of English Language, University of Seville, Seville, Spain, ²ENT Clinic at Hospital Virgen Macarena, Seville, Spain, and ³Department of Physiology, School of Pharmacy, University of Seville, Seville, Spain

*Correspondence address. Departamento de Filología Inglesa (Lengua Inglesa), Facultad de Filología, calle Palos de la Frontera s/n, Sevilla 41004, Spain. Tel: +34-954-551-588; Fax: +34-954-551-516; E-mail: teresals@us.es

Abstract

In centrally related hearing loss, there is no apparent damage in the auditory system, but the patient is unable to hear sounds. In patients with cortical hearing loss (and in the absence of communication deficit, either total or partial, as in agnosia or aphasia), some attention-related or language-based disorders may lead to a wrong diagnosis of hearing impairment. The authors present two patients (8 and 11 years old) with no anatomical damage to the ear, the absence of neurological damage or trauma, but immature cortical auditory evoked potentials. Both patients presented a clinical history of multiple diagnoses over several years. Because the most visible symptom was moderate hearing loss, the patients were recurrently referred to audiological testing, with no improvement. This report describes the use of long-latency evoked potentials to determine cases of cortical hearing loss, where hearing impairment is a consequence of underdevelopment at the central nervous system.

INTRODUCTION

We report two cases of centrally related hearing loss in children (8 and 11 years old) affected by an underdeveloped maturational processing in the primary auditory cortex that is initially observable through objective and subjective hearing impairment. Traditionally, cortical auditory evoked potentials (CAEPs) have been used to obtain information of the area of the brain where the auditory cortex (primary and secondary) is located [1]. Long-latency evoked potentials (LLEPs) are said to relate to attention, memory and auditory discrimination skills [2, 3]. We believe that LLEP is a robust test that can be applied to identify cortical hearing loss associated with immature central processing.

CASE REPORT

Case 1

An 8-year-old boy was referred to the ENT clinic with a suspicion of objective hearing loss. The boy was initially diagnosed

with a probable attention deficit hyperactivity disorder, but no language-based learning disability had been found by a preliminary psychological assessment. A pure tone audiometry (250–4000 Hz) demonstrated thresholds of 45–60 dB hearing level (HL) for the right ear and 50–60 dB HL for the left ear (Fig. 1A). Tympanometry, transient evoked otoacoustic emissions (TEOAE) as well as crossed and uncrossed acoustic reflexes were normal. A neurological examination using CT scan revealed no significant findings in the anatomy of the ear. An EEG test to discard tumor/trauma showed normal results. A well-formed brainstem auditory evoked potential (BAEP) test was recorded bilaterally (Fig. 1C). Results in the perception test (identification of two-syllable words at different HL levels) proved 100% accuracy at 50 dB HL for the right ear and 100% at 35 dB HL for the left ear. He then performed an LLEP test in three sweeps (80, 60 and 40 dB normal hearing level (nHL) tone bursts at 250–2000 Hz) in the right and left ears, alternatively, which shows the absence of CAEPs for the 40 dB nHL stimulation and polyphasic interwave morphology (Fig. 2A). The patient was widely awake during the procedure with eyes open.

Received: December 29, 2015. Revised: February 2, 2016. Accepted: February 4, 2016

© The Author 2016. Published by Oxford University Press.

This is an Open Access article distributed under the terms of the Creative Commons Attribution Non-Commercial License (<http://creativecommons.org/licenses/by-nc/4.0/>), which permits non-commercial re-use, distribution, and reproduction in any medium, provided the original work is properly cited. For commercial re-use, please contact journals.permissions@oup.com

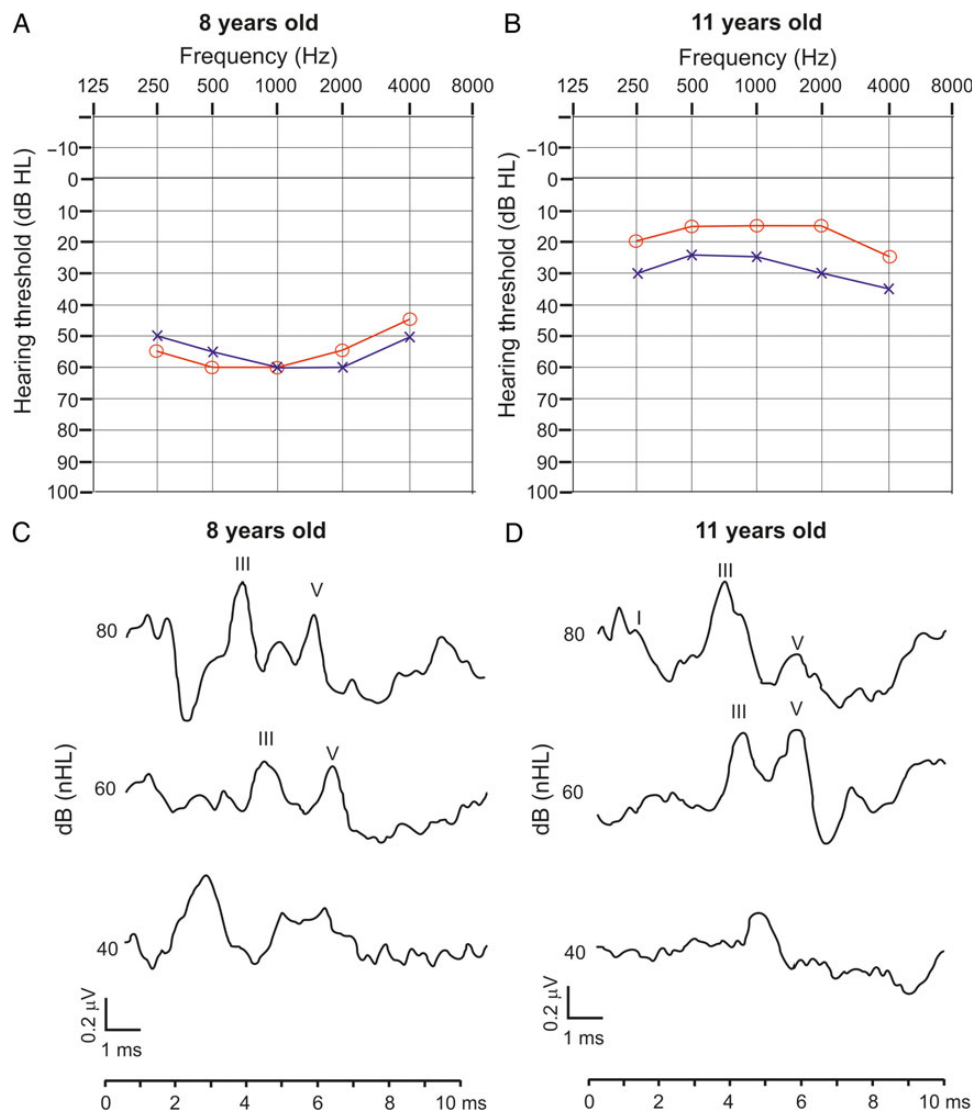


Figure 1: Audiogram and BAEP results for the 8-year-old child (on the left) and the 11-year-old child (on the right). (A) Hearing threshold for both right and left ears for the 8-year-old child. Note that moderate loss 45–60 dB HL at 250–4000 Hz. (B) Hearing threshold for both right and left ears for the 11-year-old boy, very mild at 2000–4000 Hz. (C) The BAEP test for the 8-year-old boy at three intensity levels (80–60–40 dB nHL) shows normality in the peripheral nervous system. (D) The BAEP test for the 11-year-old child is normal.

Case 2

An 11-year-old boy presented at the Otorhinolaryngology day ward with a medical history of moderate language-based learning disorders. The boy was referred to the ENT clinic with a suspicion of objective and subjective hearing loss. The patient had a previous pathology of bone dysplasia in the left malar. A pure tone audiometry showed normal hearing (Fig. 1B), the results of the tympanogram and TEOAE were normal and the acoustic reflexes (stapedius reflex) of the middle ear showed no anatomical disorder. Results in the perception test proved 100% accuracy at 40 dB HL for the right ear and 100% at 50 dB HL for the left ear. A neurological examination using CT scan revealed no significant findings in the anatomy of the ear. Neurological history was complemented with a BAEP test, which proved normality (Fig. 1D). The LLEP test shows that waves with polyphasic morphology plus no CAEP could be identified for the 60 and 40 dB nHL stimulations (Fig. 2B). The recording of CAEPs occurs while the patient was awake with eyes open.

DISCUSSION

Recent studies increasingly use CAEPs as an early indicator of cognitive impairment (e.g. dementia) [4]. We present the same method adapted to children to identify immature cortical development that may only be appreciated through moderate hearing loss. Patients in this report present no lesion on the temporal lobe or any other neurologically related pathology. There is no visible damage to the anatomy of the auditory system or the peripheral nervous system. They share a long clinical history and moderate language-based deficit and/or attention. We have used latency (ms) but not amplitude as the measure to classify CAEPs (P1, N1a, N1b, P2 and N2). Amplitude may not be an objective measure for the population described here because its objective value decreases with attention, so it does not seem appropriate for younger patients or patients with a suspicion of attention deficits [3].

Maturation changes in CAEPs include decreases in latency and amplitude as well as dynamic morphological changes [5].

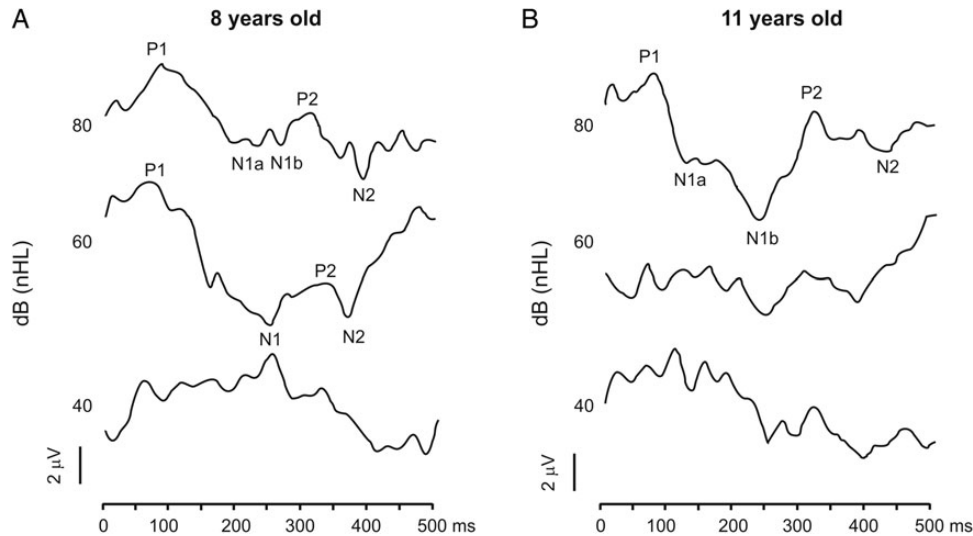


Figure 2: LLEP results for the 8-year-old child (on the left) and the 11-year-old child (on the right). (A) LLEP test for the 8-year-old child. Note that interwave amplitude decreases with lower intensity stimulation. CAEPs can be clearly observable at 80 dB nHL with double negativity. Latency values are delayed for all CAEPs. Even though similar wave morphology is observed at 60 dB nHL, CAEPs are not clearly found. At 60 and 40 dB nHL, interwave amplitude is polyphasic, with multiple periods between peaks, showing immature development according to the literature. (B) LLEP test for the 11-year-old boy. CAEPs can be observed at 80 dB nHL with double negativity. Latency values are delayed for all CAEPs, especially for N2. Interwave morphology is very irregular, with multiple periods, which is not normal for pre-teen age. Cortical maturation of the older child is similar to the younger boy, which recommends further neuropsychological testing.

We have observed that interwave amplitude decreases with stimulus intensity, which was predictable. However, polyphasic morphology (multiple periods between CAEPs) should not be present in children older than 3 years [3, 6]. This fact is so obvious that it prevents from the identification of specific CAEPs. The neural generators of P1 originate in the thalamus–cortical projections to the auditory cortex and may represent the first recurring activity in the cortex. The emergence of N1, on the other hand, has been compared with the maturation of axon neurofilaments and various critical stages in speech perception [7]. We could assume then that both P1 and N1 reflect second-order processing of the auditory cortex. Normal values for P1 can be found ~97 ms for 7–8 years and ~77 ms for 11–12 years [8]. In our case, these values seem normal (78 ms) for the 8-year-old child and slightly late (89.5 ms) for the 11-year-old child. However, more clear is the emergence of double negativity represented by N1a and N1b [6]. Latencies are delayed for the rest of CAEPs. The P2 component measures were 291.5 ms in the case of the 8-year-old child and 312.65 ms for the 11-year-old child (vs. normal 150 ms [8]). The N2 component is present in the two patients, with late latencies (~400 ms for both patients). Studies have also shown that the N2 component may be used as an objective measure of temporal processing ability [9, 10]. Normal values for N2 are 243 ms (for 8 years old) and 226 ms (for 11 years old).

Overall, the preliminary diagnosis of hearing impairment in these patients needs to be complemented as a case of cortical hearing loss. The case of the pre-teen is especially important because objective and subjective audiological testing discarded severe hearing impairment, yet LLEP test indicates similar late maturation when compared with the younger boy. These cases are becoming more recurring in our clinic, which advises for the use of LLEP for two reasons: first, to identify whether we are dealing with a case of cortical loss and secondly, to assess the need to complement with neuropsychological testing (in the absence of neurological trauma/pathology). In the cases reported, values of P1 (78 and 89.5 ms, respectively) were within the normal range, with double N1 component and late latencies for P2–N2

when compared with standard values (291.5 and 312.65 ms for P2, respectively, vs. normal 150 ms; ~400 ms for N2 vs. normal 243–226 ms, respectively). CAEP amplitude was not considered, but the polyphasic morphology of the waves and the absence of some CAEPs at various intensity levels were used to demonstrate underdevelopment at the cortical area that advises for complementary neuropsychological study.

In conclusion, this case report gives evidence of two children who display some learning difficulties, as reported by caregivers and psychologists. The two children are initially diagnosed with light to moderate hearing loss by the delivery of subjective tests (pure tone audiometry and speech audiometry). However, TEOAE and immittance audiometry (stapedius reflex) proved normal for both patients. In the absence of any anatomical damage to the ear or neurological lesion/trauma as tested by CT scan and EEG, a combination of two electrophysiological tests (BAEP and LLEP) led to the final diagnosis of a centrally related hearing loss: with normal BAEP results, late latency in LLEP proved the lack of maturational central processes in both children, which coincide with psychological evidence. These results advise for complementary neuropsychological study.

ACKNOWLEDGEMENTS

The authors express their gratitude to Serafín Sánchez-Gómez, MD, PhD, Head of Service of the ENT Clinic, Hospital Virgen Macarena, Seville (Spain), for his support and clinical supervision.

CONFLICT OF INTEREST STATEMENT

None declared.

FUNDING

This work was supported by the Ministry of Economy and Competitiveness of Spain (FFI2010-18205) and the Secretary of State for Research, Development and Innovation.

ETHICAL APPROVAL

Research presented in this manuscript has obtained ethical approval by Hospital Virgen Macarena, Sevilla, and University of Seville (Spain).

CONSENT

Participants in this report and parents/tutors have been informed on details of the study, including benefits in participation, possible risks, right to leave without previous notice and all contact information from responsible researchers. They have declared their acceptance to participate in the study and have signed a consent form.

GUARANTOR

The study has been carried out under constant clinical supervision by Serafín Sánchez-Gómez.

REFERENCES

- Sharma A, Cardon G, Henion K, Roland P. Cortical maturation and behavioral outcomes in children with auditory neuropathy spectrum disorder. *Int J Audiol* 2011;50:98–106.
- Näätänen R. *Attention and Brain Function*. Hillsdale, New Jersey: Erlbaum Associates Publishers, 1992.
- Wunderlich JL, Cone-Wesson BK. Maturation of CAEP in infants and children: a review. *Hear Res* 2006;212:212–23.
- Lister JJ, Bush AL, Andel R, Matthews C, Morgan D, Edwards JD. Cortical auditory evoked responses of older adults with and without probable mild cognitive impairment. *Clin Neurophysiol* 2016;127:1279–87.
- Choudhury N, Benasich AA. Maturation of auditory evoked potentials from 6 to 48 months: prediction to 3 and 4 year language and cognitive abilities. *Clin Neurophysiol* 2011;122:320–38.
- Sharma A, Kraus N, McGee TJ, Nicol TG. Developmental changes in P1 and N1 central auditory responses elicited by consonant-vowel syllables. *Electroencephalogr Clin Neurophysiol* 1997;104:540–5.
- Eggermont JJ, Ponton CW. Auditory-evoked potential studies of cortical maturation in normal hearing and implanted children: correlations with changes in structure and speech perception. *Acta Otolaryngol* 2003;123:249–52.
- Gilley PM, Sharma A, Dorman M, Martin K. Developmental changes in refractoriness of the cortical auditory evoked potential. *Clin Neurophysiol* 2005;116:648–57.
- Almeqbel A, McMahon C. Objective measurement of high-level auditory cortical function in children. *Int J Pediatr Otorhinolaryngol* 2015;79:1055–62.
- Sussman E, Steinschneider M, Gumenyuk V, Grushko J, Lawson K. The maturation of human evoked brain potentials to sounds presented at different stimulus rates. *Hear Res* 2008;236:61–79.