

productive and may even worsen the situation. Prolonged disability is usual, but repeated supportive visits to a therapist may improve the condition.

## REFERENCES

1. Angelini, G., Meneghini, C. L. & Vena, G. A.: Secretan's syndrome: an artefact oedema of the hand. *Contact Dermatitis* 8: 345, 1982.
2. Belenger, M. & Van der Elst, E.: Oedema chronique du dors de la main. *Phlébologie* 18: 69, 1965.
3. Blauth, W.: Ein Beitrag zum traumatischen Handrückenödem. *Monatsschr Unfallheilkd* 63: 189, 1960.
4. Van Demark, R. E., Koucky, J. D. & Fischer, F. J.: Peritendinous fibroma of the dorsum of the hand. *J Bone Joint Surg* 30A: 284, 1948.
5. Van der Elst, E.: Dorsal edema of the hand, so-called Secretan's edema. *Z Unfallmed Berufskr* 53: 112, 1960.
6. Fleming, J. P.: Secretan's disease. *Can J Surg* 9: 78, 1966.
7. Frax, I. & Coughlin, B. E.: The treatment of factitial disease. *Psychosomatics* 12: 117, 1971.
8. Grobmyer, A. J., Bruner, J. M. & Dragsted, L. R.: Closed lymphangioplasty in Secretan's disease. *Arch Surg* 97: 81, 1968.
9. Krupp, N. E.: Self-caused skin ulcers. *Psychosomatics* 18: 15, 1977.
10. Leriche, M.: Oedème dur aigu post-traumatique de la main avec impotence fonctionnelle complète. Transformation soudaine cinq heures après symphathec-tomie humerale. *Lyon Chir* 20: 814, 1923.
11. Lucky, C. A. & Moon, H. D.: Hard dorsal post-traumatic edema of the hand. *Plast Reconstr Surg* 2: 563, 1947.
12. Omer, G. E., Riordan, D. C., Conran, P. B. & Winter, R.: Peritendinous fibrosis of the dorsum of the hand in monkeys. *Clin Orthop* 62: 251, 1969.
13. Reading, G.: Secretan's syndrome: Hard edema of the dorsum of the hand. *Plast Reconstr Surg* 65: 182, 1980.
14. Saferin, E. H. & Posch, J. L.: Secretan's disease. *Plast Reconstr Surg* 58: 703, 1976.
15. Secretan, H.: Oedème dur et hyperplasie traumatique du metacarpe dorsal. *Rev Med Suisse Romande* 21: 409, 1901.
16. Smith, R. J.: Factitious lymphedema of the hand. *J Bone Joint Surg* 57A: 89, 1975.

## "Keratosi Palmoplantar Striata" (Brunauer-Fuhs Type)

M. Ortega, J. Quintana and F. Camacho

*Department of Medical-Surgical Dermatology and Venereology, University of Seville, Seville, Spain*

Received November 2, 1982

*Abstract.* Keratosis palmoplantar striata (Brunauer-Fuhs type), in three generations. The clinical, etiopathogenic and therapeutic aspects of this rare keratoderma are discussed.

*Key words:* Keratosis palmoplantar striata; Etiopathogenic aspects; Retinoid acid

In the group of palmoplantar keratoderma, according to Franceschetti & Schnyder's classification (7), the form which stands out, due to its exceptionality, is the one described by Brunauer (4), and Fuhs (8), which because of the linear appearance of the keratotic elements on the palms, was given the name "keratosis palmaris striata" by Siemens (10) 5 years later. This keratoderma is defined by the following characteristics: (a) dominant autosomal inheritance, (b) appearance in puberty or adulthood, (c) brought on by mechanical trauma, in general, of an occupational nature, (d) linear keratotic elevations on the palms, (e) elements of these same characteristics, but arranged in small islets, "areata form", on the soles.

Recently, we have had the opportunity, in the Department of Medical-Surgical Dermatology and Venereology at the University of Seville, to study a family affected by this process, and we will now go on to explain our case "princeps", and to discuss briefly the aspects which merit greater attention.

### CASE REPORT

M. R. R., male, 35 years of age, a cooper, born in Dos Hermanas (Seville), first consulted us in May 1982, because since the age of 23, he had suffered from the appearance of keratotic elements on the palms. The areas in which the complaint was particularly more evident, were those subject to friction and pressure. The condition improved when the patient abstained from work. He also had a similar, though very painful condition on the soles of his feet. Both his hands and feet were submitted to a process of topical treatment and surgery, but the condition always reappeared. His father, brother and daughter were affected by the same process (Fig. 1).

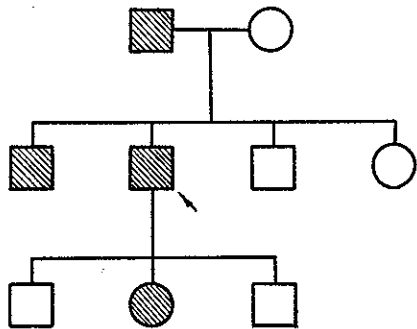


Fig. 1. Pedigree of affected family.

On examination, we observed yellowish, chapped areas of linear keratosis elements on the palm surface of the fingers, which extended to the palms and which were more evident on the right hand (Fig. 2), and keratoderma on the soles, specifically on the pressure points.

The analysis carried out was normal and the dermopathological test revealed intense orthokeratotic hyperkeratosis on the swollen stratum lucidum, hypergranulosis and papillomatosis.

*Treatment.* Oral retinoid acid (0.33 mg/kg/day) and topical cream (retinoid acid 0.3%) afforded obvious improvement, at least while the patient remained absent from his work.

#### DISCUSSION

The description of the keratoderma suffered by our patient, and observed in some of his relatives, is a clear example of the Brunauer-Fuhs type, charac-

terized by linear or striata keratose elements on the palms. Similar descriptions of this affection have been published by Aguiar Pupo (1), Basex (2), Thiers & Chaniel (11), and are easily distinguished from the Unna-Thost type (12) (13) and others affecting the soles, and related to mechanical traumas which, although normally occurring in islets "Areata form" (6) (7) (9) (11), have sometimes been found in a more diffuse form (4) (8) (10).

The etiopathogenic aspects also merit our attention. The dominance of one gene over three generations means that we can be sure that this keratoderma is dominant autosomal, and this fact also puts in doubt the non-family-related cases, described as autonomous forms, since, even if all the relatives were examined, it would be possible to find only minimal elements which generally go unnoticed (6).

Its late appearance, usually between the ages of 15 and 20, a fact which is only borne out by the daughter of our patient, since in the other patients it appeared in their twenties, and the part played by mechanical and occupational traumas, may be explained by the "geno-ecology" theory of Bologna (3), by considering it to be a bipolar complaint, with both hereditary predisposition and determining factors.

Although our results with oral and topical retinoid acid therapy have been satisfactory, both on the palms and on the soles, we feel that it might

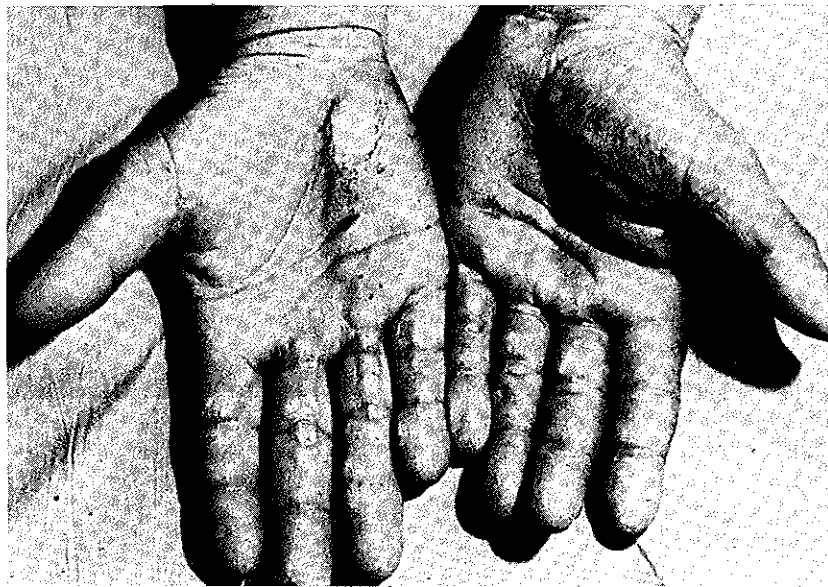

Fig. 2. Keratose striata, elements on the palms.

be another of the subsidiary keratinization disorders which could be treated with aromatic retinoid (Ro. 10-9359), especially in cases which do not respond well to the former, without forgetting that, due to its crippling nature, if therapeutic medicine were not successful, recourse might be taken to surgical treatment.

## REFERENCES

1. Aguiar Pupo, J.: Queratodermias palmoplantares. *Dermatologia (Rev Mexicana)* 6: 18, 1962.
2. Basex, A., Salvador, A., Dupre, A., Parant, M., Bessiere, L.: Keratodermie palmoplantaire type Thost-Unna, pachionychie et kératose hypertrophique du gland. *Bull Soc Franç Dermatol Syph* 64: 800, 1957.
3. Bologa, E. I.: Le complexe géno-écologique dans le déterminisme des kératoses palmoplantaires. *Ann Dermatol Venereol* 97: 259, 1970.
4. Brunauer, S. R.: Zur Vererbung des Keratomas hereditarium palmare et plantare. *Acta Dermatovener (Stockholm)* 4: 489, 1923.
5. Buschke, A. & Fischer, W.: Keratoderma maculosa disseminata symetrica palmaris et plantaris. *Ikongraphia Dermatologica* 5: 183, 1910.
6. Degos, R.: *Dermatologie*, pp. 664j-664k. Flammarion, 1956.
7. Franceschetti, A. & Schnyder, U. W.: Versuch einer klinisch-genetischen Klassifikation der hereditären Palmoplantar-Keratosen unter Berücksichtigung assoziierter Symptome. *Dermatologica* 120: 154, 1960.
8. Fuhs, H.: Zur Kenntnis der herdweisen Keratosen an Händen und Füßen. *Acta Dermatovener (Stockholm)* 5: 11, 1924.
9. Ocaña Sierra, J. Blesa, G. & Wilhelmi, M. L.: Queratodermias palmoplantares. *Actas Dermatol Sif* 72: 513, 1981.
10. Siemens, H. W.: Keratosis palmoplantaris striata. *Arch Dermatol Syph (Berlin)* 157: 392, 1929.
11. Thiers, H. & Chaniel, G.: Polykeratose de Touraine. *Ann Dermatol Vénéreol* 84: 269, 1957.
12. Thost, A.: Über erbliche Ichthyosis palmaris et plantaris. *Inaug. Dissertation*, 37 p., Horning, 1980.
13. Unna, P. G.: Über das Keratoma palmare et plantare hereditarium. *Arch Dermatol Syph* 15: 231, 1883.
14. Zmegac, Z. & Sarajlic, M. V.: A rare form of an inheritable palmar and plantar keratosis. *Dermatologica* 130: 40, 1964.