

Letters to the Editor

Perforated, fistulized-to-skin ileum within a large incarcerated umbilical hernia

Palabras clave: Íleon perforado. Perforación. Hernia. Cirugía.

Key words: Perforated ileum. Perforation. Hernia. Surgery.

Dear Editor:

A 76-year-old female patient presented to our hospital because of skin necrosis with purulent exudate from a four to five-standing relapsed umbilical hernia with no associated fever, vomiting, or bowel obstruction signs. Her relevant history included diabetes mellitus and high blood pressure, as well

as hernioplasty for an umbilical hernia that relapsed twice. Examination reveals a large tender, irreducible relapsed umbilical hernia apparently including multiple sacs. Laboratory testing revealed increased urea and creatinin levels, as well as leukocytosis and neutrophilia. The lesion is explored in the outpatient minor surgery room, and reveals no subcutaneous abscess but a suppurating hernial sac; hence we ordered an emergency abdominal CT scan (Fig. 1) for suspected perforation of hernial contents (multisacculular umbilical hernia with the lower sac showing thickened intestinal loops, and a fistula and abscess in its lower portion, all of this consistent with intestinal perforation, with no bowel obstruction signs in the remaining intestine). In view of these findings a surgical procedure is performed, where a post-laparotomy multisacculular hernia with perforated distal ileum is uncovered; a resection with ileal latero-lateral anastomosis is carried out, followed by herniorrhaphy and musculo-aponeurotic border suture using Quenu's technique (the pathology report described it as ulcerated ischemic ileitis with

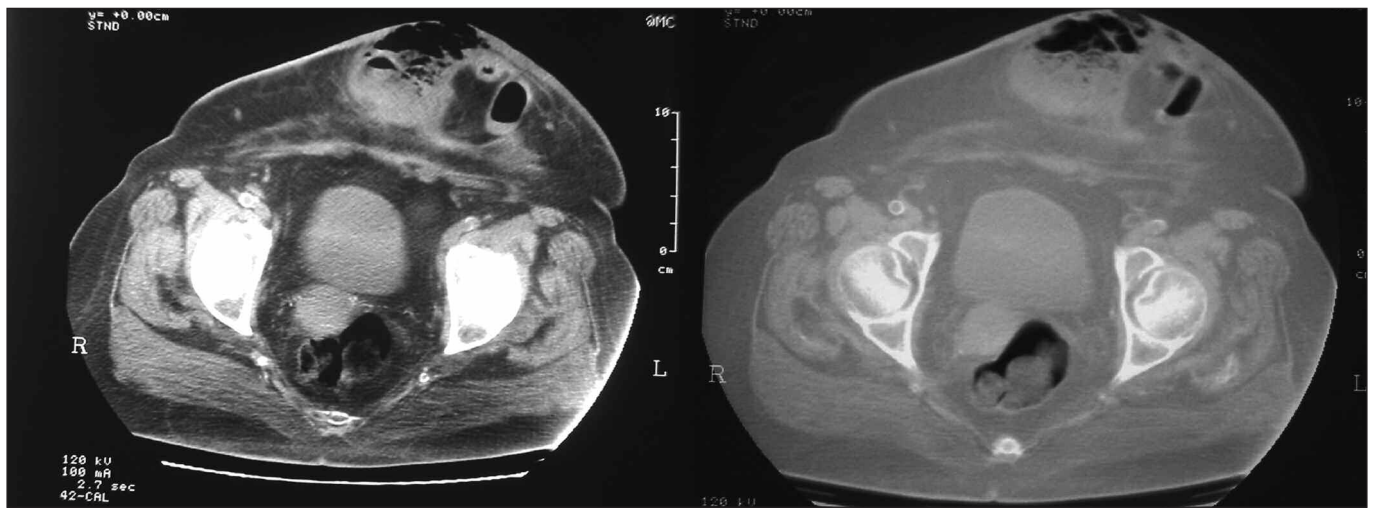


Fig. 1. Abdominal CT images: Left (abdominal CT with IV contrast). Right (abdominal CT with pulmonary window to identify intraperitoneal gas). A large umbilical hernia may be seen that includes grossly thickened small-bowel loops with accessory collection; the hernia itself seems to have no continuity with the outside.

transmural perforation). It initially progressed torpidly with septic shock, and then to hemodynamic stabilization and extubation after 72 hours, with the patient being transferred to the ward on the fifth postoperative day; the remaining postoperative period was uneventful, and the patient was discharged after 11 days. She is now being followed up at the Surgery outpatient clinic with a satisfactory outcome.

Despite this being the era of hernial prosthesical surgery, in the face of a challenging defect that has already required more than two procedures with both major mesh types in various planes, reconstruction must be more physiologically oriented, and even procedures using muscle flaps to set up a new continent abdominal wall should be rescued from oblivion. Thus, we may perform a herniorrhaphy with non-reabsorbable or long-term reabsorbable material, Quenu or Gibson type, using the anterior recti for abdominal reconstruction, or Wolti-Eudel type, using flaps from rectus muscle sheaths (1).

Large-diameter multisaccular abdominal hernia usually includes both small and large bowel segments; ileal presentation as a cause of perforation and fistulization outside is a rare finding (2), with such events being more common in acute appendicitis or colon adenocarcinoma (3,4), and possibly in sudden inflammatory bowel disease. In the case reported our patient had long-term partially incarcerated hernial contents with a potential for ischemia, necrosis, and fistula induction, the latter from the herniated ileal portion to the skin, with no associated intestinal obstruction symptoms (2,5).

Postoperative management for this condition is usually challenging and is associated with poor prognosis, particularly due to renal involvement, as long-standing metabolic acidosis with difficult-to-correct electrolytic unbalance is usually present. Furthermore, patients commonly develop septic shock, which usually results in patient's death. Therefore treatment is aimed at volume replacement, acid-base balance correction, and renal function maintenance, and also includes empiric broad-spectrum antibiotic therapy, with culture-antibiogram from intraoperative specimens to guide further antibiotic use. Patients with septic shock and a continued need for vasoactive drugs despite

adequate resuscitation with fluids may have an indication for low-dose hydrocortisone (200-300 mg/day in split doses or continuous infusion, for up to seven days, alone or combined with enteral fludrocortisone) (6). The risk for surgical wound infection and relapsed wall defect is higher in emergency abdominal wall surgery, hence periodical follow-up to monitor hernial repair continence is recommended.

J. M. Suárez Grau, J. L. García Moreno, F. Docobo Durántez,
M. Socas Macías, J. M. Álamo Martínez, F. López Bernal,
C. Rubio Chaves, G. Suárez Artacho, J. A. Martín Cartes and
S. Morales Méndez

*General Surgery and Gastroenterology Department.
Universitary Hospital Virgen del Rocío. Seville, Spain*

Bibliografía

1. Mathes SJ, Steinwald PM, Foster RD, Hoffman WI, Anthony JP. Complex abdominal wall reconstruction: A comparison of flap and mesh closure. *Annals of Surgery* Vol. 232, No. 4; 586-96.
2. Álvarez-Zepeda C, Hermansen-Truan C, Valencia-Lazo O, Azolas-Marcos R, Gatica-Jiménez F, Castillo-Avendano J. Necrotizing fasciitis of the abdominal wall secondary to a perforated sigmoid diverticulum in a Spiegel's hernia. A case report. *Cir Cir* 2005; 73 (2): 133-6.
3. Limas C, Soultanidis C. Perforated appendicitis presenting as incarcerated hernia. *Minerva Pediatr* 2004; 56 (5): 551.
4. Kouraklis G, Kouskos E, Glinavou A, Raftopoulos J, Karatzas G. Perforated carcinoma of the sigmoid colon in an incarcerated inguinal hernia: Report of a case. *Surg Today* 2003; 33 (9): 707-8.
5. Semeniaka OV, Ivanov AV, Trofimov AN. Rare complication of giant abdominal wall hernia by the small intestine perforation and the hernial sac phlegmon. *Klin Khir* 2005; (2): 52-3.
6. Annane D, Sébille V, Charpentier C, Bollaert PE, Francois B, Korach JM, et al. Effects of treatment with low doses of hydrocortisone and fludrocortisone on mortality in patients with septic shock. *JAMA* 2002; 288: 862-71.