

Letters to the Editor

Mesenteric fibromatosis: a rare entity

Key words: Acute cholecystitis. Mesenteric fibromatosis.

Dear Editor,

We present the case of a 72-year-old woman who visits the emergency service with a 2-week history of pain in right upper abdominal quadrant, vomits and feverishness. The patient does not report alterations in the intestinal habit. The examination does not show peritoneal irritation or mucocutaneous jaundice. In the personal history of the patient we find mastectomy due to breast cancer 31 years before.

Laboratory analyses reveal leukocytosis of up to 16,000/mm³ and neutrophils were 84.6%. An abdominal echography is suggestive of acute cholecystitis.

We initiate antibiotic therapy and the patient is admitted in order to study the evolution. After 4 days, the patient shows significant worsening of clinical symptoms and she undergoes emergency surgery. We perform laparotomic cholecystectomy. The anatomopathologic study of the resected piece reveals severe acute cholecystitis. Four days after surgery vomits and fever reappear. A new echography discards intraabdominal fluid collections or any other significant findings.

During the following days, vomits persist and a new symptom appears, constipation. Abdominal x-rays do not show dilation of intestinal loops. We administer hydrosoluble contrast which in the contrast plate is found in the rectal ampulla. Abdominal CT scan reveals a lesion of 8 cm in the left epigastrium which affects the loops and could be the cause of the clinical symptoms.

In view of the results obtained in the CT scan and the condition of the patient, we perform surgical resection of a tumor of 15 cm which seems to depend on the proximal jejunum and is located in Treitz's angle (Fig. 1). Intraoperative biopsy discards

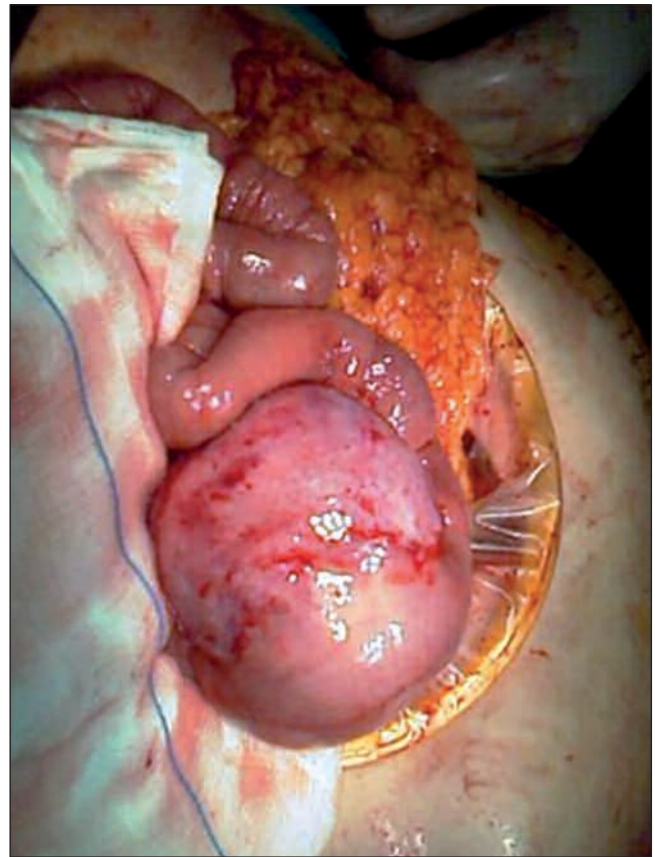


Fig. 1. Mass located at Treitz's angle.

the malignancy of the lesion and the subsequent analysis of the resected sample establishes the diagnosis of aggressive mesenteric fibromatosis not affecting the ganglia.

The evolution of the patient after surgery was favourable and she was discharged 10 days later without symptoms.

Discussion

Mesenteric fibromatosis is a rare variety of desmoid tumor (0.03-1%) although it is considered the most common primary tumor involving the mesentery. It evolves from fibrous proliferations and is usually benign, but its capacity of local invasion turns it into an entity of intermediate malignancy. It has a higher incidence in women with a ratio of 2:1 and mean age of patients is 35.

It can be located inside or outside the abdomen. In half of the cases it appears in the anterior abdominal wall, in 41% of patients in the mesentery and in 9% in the retroperitoneum. When it is located inside the abdominal cavity it usually appears in the small intestine, other locations being uncommon.

The etiology of these lesions is not clear although they are somewhat associated to prior trauma or abdominal surgery (10-12%) and although hormonal influence is not well established, some authors report a higher incidence during hyperestrogenism states (pregnancy, hormonal contraception) and up to 25% of patients have shown APC gene mutation, which also occurs in Gardner's syndrome.

The symptoms are unspecific and include abdominal pain, postprandial fullness, hydronephrosis, bleeding and even acute abdomen as a result of perforation of hollow viscera. Fibromatosis can be palpated due to the great mobility of the mesentery which allows it to grow without clinical consequences. Occasionally, these lesions are accidentally diagnosed during study of abdominal tumors. The diagnostic test of choice is tomography which reveals a heterogeneous mass in comparison to the mesentery and possibly affecting adjacent structures.

Surgery is the treatment of choice but due to the complexity of total resection recidives are common (45%). As a result, other therapies complementary to surgery are proposed. Whereas imatinib mesilate does not yield favourable results, treatment with doxorubin and dacarbazine have achieved total remission in some patients.

Other therapeutic alternatives include radiotherapy in combination with surgery, antiestrogens (tamoxifen) and NSAIDs, the last two without definite results.

After diagnosis and therapy, a colonoscopy and/or opaque enema must be performed in order to discard the presence of adenomatous polyps in the colon, typical of Gardner's disease and which worsen the prognosis of such syndrome and determine the treatment. It seems that fibromatosis is more common after surgical treatment of Gardner's syndrome. In this case, it would be advisable to delay cholecystectomy until the adult age.

V. Gómez Cabeza de Vaca, D. Molina García, J. Cañete Gómez, F. López Bernal, M. Flores Cortés, C. Palacios González, E. Prendes Sillero and F. Pareja Ciuró

Department of Emergency Surgery. University Hospital Virgen del Rocío. Sevilla, Spain

Recommended references

1. Ezumi K, Yamamoto H, Takemasa I, Nomura M, Ikeda M, Sekimoto M, et al. Dacarbazine-doxorubicin therapy ameliorated an extremely aggressive mesenteric desmoid tumor associated with familial adenomatous polyposis: report of a case. *Jpn J Clin Oncol* 2008; 38(3): 222-6.
2. Tanaka K, Yoshikawa R, Yanagi H, Gega M, Fujiwara Y, Hashimoto-Tamaoki T, et al. Regression of sporadic intra-abdominal desmoid tumour following administration of non-steroidal anti-inflammatory drug. *World J Surg Oncol* 2008; 6: 17.
3. Durno C, Monga N, Bapat B, Berk T, Cohen Z, Gallinger S. Does early colectomy increase desmoid risk in familial adenomatous polyposis? *Clin Gastroenterol Hepatol* 2007; 5(10): 1190-4.
4. Nieuwenhuis MH, De Vos Tot Nederveen Cappel W, Botma A, Nangengast FM, Kleibeuker JH, et al. Desmoid tumors in a dutch cohort of patients with familial adenomatous polyposis. *Clin Gastroenterol Hepatol* 2008; 6(2): 215-9.