

Journal section: Oral Surgery
 Publication Types: Research

doi:10.4317/medoral.21812
<http://dx.doi.org/doi:10.4317/medoral.21812>

Prospective study of the 532 nm laser (KTP) versus diode laser 980 nm in the resection of hyperplastic lesions of the oral cavity

Patricia Bargiela-Pérez ¹, Jorge González-Merchán ², Rosa Díaz-Sánchez ², Maria-Angeles Serrera-Figallo ¹, Gerd Volland ¹, Martin Joergens ¹, Jose-Luis Gutiérrez-Pérez ³, Daniel Torres-Lagares ¹

¹ DDS, PhD. Dental School. University of Seville, Spain

² DDS. Dental School. University of Seville, Spain

³ DMD, PhD. Dental School. University of Seville, Spain

Correspondence:

Dental School – University of Seville
 C/ Avicena s/n 41009 Sevilla, SPAIN
danieltl@us.es

Bargiela-Pérez P, González-Merchán J, Díaz-Sánchez R, Serrera-Figallo MA, Volland G, Joergens M, Gutiérrez-Pérez JL, Torres-Lagares D. Prospective study of the 532 nm laser (KTP) versus diode laser 980 nm in the resection of hyperplastic lesions of the oral cavity. Med Oral Patol Oral Cir Bucal. 2018 Jan 1;23 (1):e78-85.

<http://www.medicinaoral.com/medoralfree01/v23i1/medoralv23i1p78.pdf>

Received: 14/01/2017
 Accepted: 18/11/2017

Article Number: 21812 <http://www.medicinaoral.com/>
 © Medicina Oral S. L. C.I.F. B 96689336 - pISSN 1698-4447 - eISSN: 1698-6946
 eMail: medicina@medicinaoral.com

Indexed in:

Science Citation Index Expanded
 Journal Citation Reports
 Index Medicus, MEDLINE, PubMed
 Scopus, Embase and Emcare
 Índice Médico Español

Abstract

Background: The aim of this study is to evaluate the resection of hyperplastic lesions on the buccal mucosa comparing the 532nm laser (KTP), versus diode 980nm laser, considering pain, scarring, inflammation and drug consumption that occurred postoperatively with each lasers.

Material and Methods: A prospective study of consecutive series of 20 patients in two groups that presents hyperplastic lesions on the buccal mucosa. The choice of the KTP laser or diode 980nm laser for the surgery was made randomly. The power used was 1.5W in both groups in a continuous wave mode with a 320 µm optical fiber. Parameters of pain, scarring, inflammation and consumption of drugs were recorded by a Numerical Rating Scale and evaluated postoperatively. These recordings were made the day of the surgery, 24 hours after, 14 and 28 days after.

Results: Pain and inflammation was light - moderate. The consumption of paracetamol was somewhat higher in the diode 980nm laser versus the KTP laser after 24 hours, although data was not statistically significant; significant differences were found after 28 days in regards to pain ($p = 0.023$) and inflammation ($p = 0.023$), but always in the absence parameter so we find no pain in both lasers. Scarring in the two types of laser showed no differences along the visits, with not detected scar retractable.

Conclusions: Although there is a slight histological difference regarding the KTP laser in the oral soft tissues for clinical use, both wavelengths are very suitable for excision of oral fibroma.

Key words: Laser surgery, Laser therapy, oral surgery, soft tissue, 980 nm diode laser, 532 nm KTP laser.

Introduction

Since Maiman in 1960 officially announced the use of the first laser (1), this technology became more and more popular. Currently laser can be found in many everyday applications. Lasers have been used in many professions, reaching the field of medicine, dentistry being no exception.

The use of laser therapy in the field of oral surgery is a common occurrence that has been developing in the last few years. Lasers in soft tissue surgery have been used since 1993, this technique acquired special importance in the field due to its many advantages in comparison to conventional surgery.

Laser technology has multiple applications in oral surgery, mainly used for the resection of soft tissue using thermal lasers such as diode, CO₂, Argon or KTP. Removal of hard tissue is reserved for thermomechanical interacting Erbium wavelengths such as ER:YAG or ER:YSGG.

In the field of laser technology, soft tissue surgery would be the application of choice. The different types of lasers give us the possibility, depending on the pathology that has to be treated, to choose the wavelength that is most beneficial for each injury.

The most common applications for soft tissue surgery are for: fibromas, mucoceles, frenectomies, vestibuloplastias, gingivectomies, angiomas, telangiectasias, leukoplakia, granulomas (2).

The oral mucosa is always susceptible to develop reactive and inflammatory reactions, because it is constantly subjected to both an external and internal stimuli.

The hyperplastic lesions represent the most frequently encountered oral mucosal lesions in humans. They may have a very different etiology and pathological features. Hyperplasia is the volume increase in tissue by the increase in cell numbers. Generally they correspond to a group of injuries caused by an exaggerated response of the oral mucosa versus low intensity chronic irritants. In the early stages, chronic irritant stimulates the formation of granulation tissue and endothelial proliferation; the tissue begins to undergo a process of fibroplasia. These lesions may regress early stages, but eventually tend to become fibrosed. The most common surgical treatment of hyperplastic lesions of soft tissue in the oral mucosa is the complete excision of the lesion. Most hyperplastic lesions of the oral cavity correspond to benign tumors or soft tissue. In the case of the buccal mucosa, the most common injuries are: fibroma, lipoma and mucocele (3,4).

The first lasers used in soft tissue surgery were the Argon laser (488 nm), the CO₂ (9600nm), the Nd: YAG laser (1064 nm) and diode laser (810nm / 980nm). Lasers with most studies in the surgical field are CO₂, Nd: YAG, Er: YAG and diode (5,6).

Diode lasers have had a very important role in the field of soft tissue surgery in the last few years. Due to their

high capacity of disinfection they are increasingly used for periapical surgery or periodontal treatment (7). These lasers are very effective in coagulation of superficial lesions, providing a dry surgical field (8). The light is constituted by a solid active medium, a semiconductor formed by using a combination of gallium, arsenic and other elements such as aluminum or indium for transforming electrical energy into light energy. They can be issued in either continuous or pulsed power and are easily transportable via optic fiber. The fiber has to be in contact with soft tissue for ablation procedures, incision and excision (9), because of the exit angle of about 42 degrees when the light exits the glass fiber. The KTP (532 nm) or "Green laser" is a solid laser with an active medium emitting in the visible portion of the spectrum (the beam is a very intense green light) produced by a diode (810 nm) laser acting as "pumps" of energy to stimulate a crystal of Nd: YAG (1064 nm). On the other hand, there is a potassium-titanyl-phosphate (KTiOPO₄) crystal located between the gain medium and the semi-reflective mirror, this way the frequency is doubled meaning the reduction of the wavelength by half resulting in a beam emission of 532 nm (10).

This laser has been introduced in the field of medicine thanks to its high affinity for hemoglobin and oxyhemoglobin, becoming very effective in vascular lesions. Furthermore, in contrast to Nd: YAG, red coloured oral tissues absorb the light in the surface avoiding unpredictable deep tissue penetration and making the application much safer.

In Dentistry this laser was used for the first time with great success for bleaching (11). Romeo *et al.* ensure that the 532 nm dental laser is the most absorbed by hemoglobin, oxyhemoglobin and melanin given wavelength. This makes it a very suitable laser for vascular lesions absorbing only on the surface without penetrating into the surrounding tissue (10). There are not many studies on this laser in the field of oral surgery.

Fornaini *et al.* studied 52 patients affected with a benign pathology in the oral soft tissue with the 532 nm or KTP. They documented the intraoperative and postoperative pain with a numeric rating scale and the need of taking drugs. All cases were treated without anesthetic infiltration (Emdla® topical anesthesia was applied). They concluded that the use of this wavelength 532 nm at low power (1 W) and a fiber of 320 microns, provided a new tool in the treatment of benign soft tissue lesions in the oral cavity, with good healing, good ability to ablation and pain (12).

We found numerous studies on the application of diode laser resection of soft tissue and its benefits (9,13,14).

In recent years, there have been some studies on the use of the 532 nm or KTP wavelength in the excision of soft tissues with apparently promising results, however few scientific articles are written about it (10,15).

Since the use of the diode laser 980 nm was introduced a few years ago, surgical time has been greatly reduced for this type of pathology. Suturing is not necessary in most cases, and the use of painkillers has been greatly reduced. Although the initial penetration for oral tissue is higher, it is very quickly, limited by tissue alteration by dry out due to the water.

Contraindications found are primarily derived from improper use. Since the depth with which penetrate the surrounding tissue can cause thermal damage, misuse can affect improper postoperative scarring and less comfort for our patients.

In comparison the 532 nm laser is majorly absorbed on the surface and to a lesser extent in depth giving very promising results in the excision of soft tissue injuries (16,17).

Both lasers raised in this study use a 320-micron fiber system for transmission and same power settings resulting in the same power density and flow. Our question therefore was, what would be the most effective laser for the surgical use in the resection of benign hyperplastic lesions of the oral mucosa evaluating by a Numerical Rating Scale, the intra and postoperative pain, inflammation, scarring and drug consumption that occurred postoperatively in the two groups.

Material and Methods

We present a prospective study of a consecutive series of 20 patients in two groups that present hyperplastic lesions on the buccal mucosa.

After having assessed whether or not the patients meet the inclusion criteria they were randomly assigned by a study coordinator who gave them identification numbers. These numbers were assigned a type of procedure. The number indicated whether the patient was to be operated with diode laser 980 nm or 532 nm laser, or KTP according to the protocol established.

The study population's formed an initial sample of 24 patients of both sexes from the Department of Oral and Maxillofacial Surgery from The Hospital Universitario Virgen del Rocío in Seville, attending the laser unit of the Faculty of Dentistry of Seville.

These patients had already been previously diagnosed as having a hyperplastic lesion on the buccal mucosa, indicating excision as a treatment thereof. All persons gave their informed consent prior to their inclusion in the study. Of the initial sample, four patients were excluded for being smokers the more than 10 cigarettes a day (others exclusion criteria were diabetes mellitus, pregnant patients, patients treated with anticoagulants or patients treated with radiotherapy in the last 12 months).

The final sample consisted of 20 patients without history or disease of interest, of which 14 were women and 6 men, aged between 18 and 70 years.

All procedures performed in studies involving human participants were in accordance with the ethical standards of the institutional and/or national research committee and with the 1964 Helsinki declaration and its later amendments or comparable ethical standards.

For the study we used a diode laser from ARC MEDICAL LASER®, FOX model manufactured in Germany. It has a wavelength of 980 nm and a variable power of 1 to 10 W. The laser can work in continuous or discontinuous mode. It is a type IV laser according to American National Standards Institute (ANSI) classification.

The 532 nm laser, or KTP laser Green, also belonged to the ARC MEDICAL LASER® Classic Green Laser Model, Germany. It has a wavelength of 532 nm and a variable power of 1 to 12 Watts. It allows work both in pulsed or continuous mode. According to ANSI classification is a laser of high power type IV.

The optical fiber used is composed of silicate glass and has a thickness of 320 µm which is the most suitable for surgery. Disposable tips were used for each surgery, the active tip of the optical fiber should leave about 3 mm from the front of the handpiece and disposable plastic tip.

Both systems were programmed in the same power of 1.5 W in continuous wave mode, with 320 µm fiber, these parameters are recommended by the manufacturer and various authors used for the excision of this type of injury.

All photographic records were made with the same camera. Everything was recorded and performed by the same investigator including surgery, photographs and data collection.

Each patient had a notebook of data collection, in which all demographics were recorded and also the health conditions. For illustrative purposes we present one of the clinical cases operated for the study with the 532 nm laser.

To begin, an initial picture of the injury was taken at a distance of 20 cm (from camera to the patient) (Fig. 1A,2A).

The patient was further anesthetized with lidocaine and epinephrine hydrochloride (20 mg / ml + 0.0125 mg / ml) solution for injection, Xilonibsa INIBSA®, Spain, infiltrating only a quarter of carpule, reaching the line indicated in the Branded carpule 0.6 mg / ml (Fig. 1B,2B).

Once anesthetized adequate protection glasses were distributed among the staff and patient present in the room.

The excision of the lesion was performed using the selected laser. After removing the injury, the power to 0.5 W was changed and passed without contact over the injury for hemostasis and tissue biostimulation (Fig. 1C,D,2C,D).

After resection ended, a photograph was taken of the lesion with a periodontal probe to measure the size.

The lesion was then sent to anatomical pathology (Fig. 1E,2E).

The postoperative care and recommendations to be followed were explained to the patient. The use of rinses were not allowed.

All patients had a Notebook Data Collection (NDC) which had to be filled and was verified by the investigator on the day of the intervention (Visit 0) in the appointment of 24 hours (Visit 1), 14 (Visit 2) and 28 days (Visit 3). The patient did a self assessment based on a visual analog scale, which measured the pain, the inflammation and scarring.

The pain felt by the patients was evaluated using a VAS

scale of 1 to 5, where: 1 = no pain 2 = moderate pain 3 = pain 4 = severe pain 5 = very strong

The inflammation, mark on a VAS scale of 1 to 5 as follows: 1 = Absence of inflammation 2 = moderate inflammation 3 = Inflammation 4 = severe inflammation 5 = Very strong inflammation

The evolution of healing was picked up by the evaluator supported with the reason for the evaluation and photographs, where 1 = good, 2 = acceptable, 3 = poor healing. The clinical course of the soft tissues were recorded by intraoral pictures (Figs. 1F,G,H, 2F,G,H).

The intake of drugs was also recorded by the patient. They were prescribed only 1 gram Paracetamol only

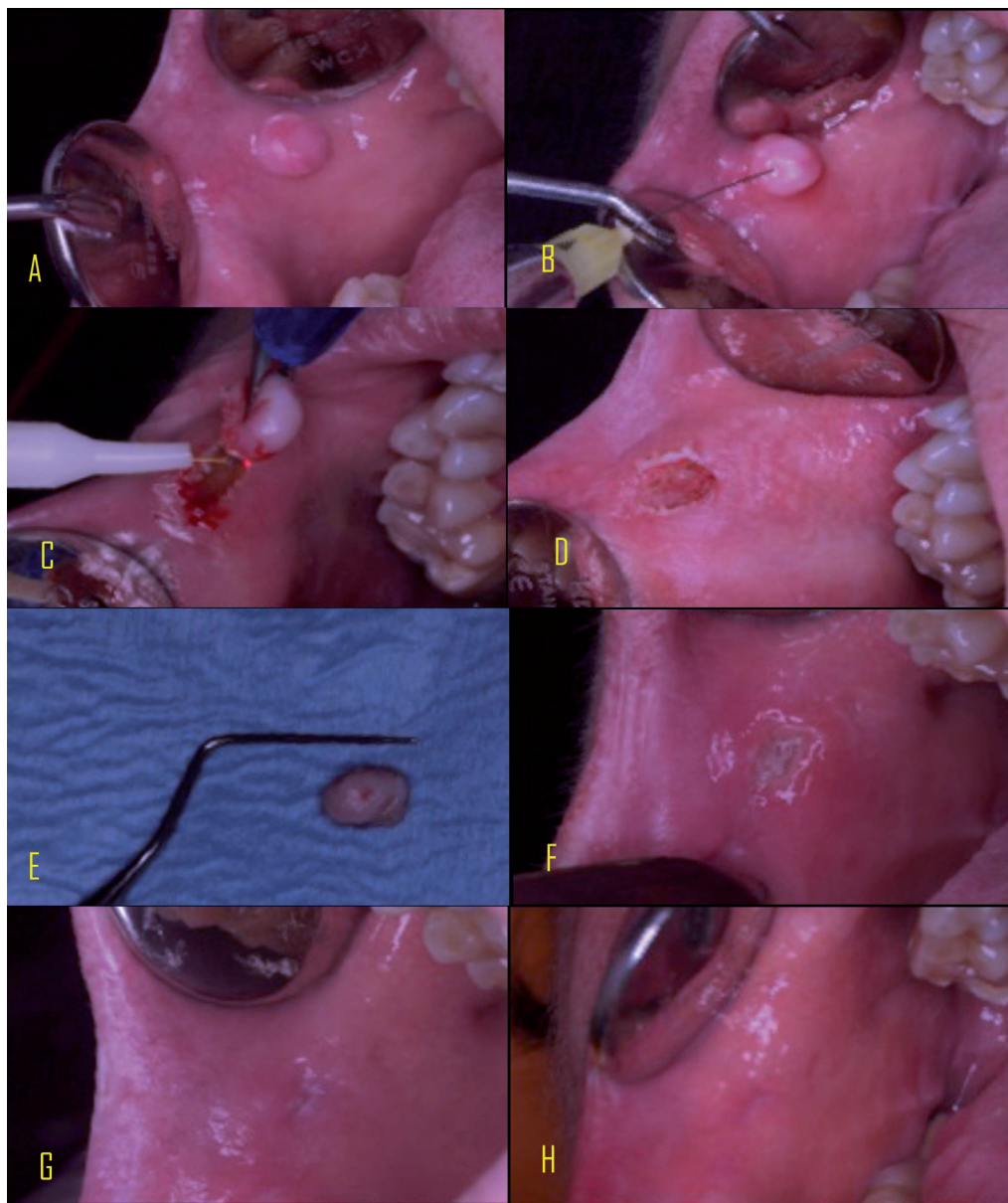


Fig. 1: Diode laser group. A Initial view of lesion; B Anesthesia ; C Excision of the lesion; D Lesion excised; E Immediate follow up; F 24 h follow up; G 14 days follow up; H 28 days follow up.

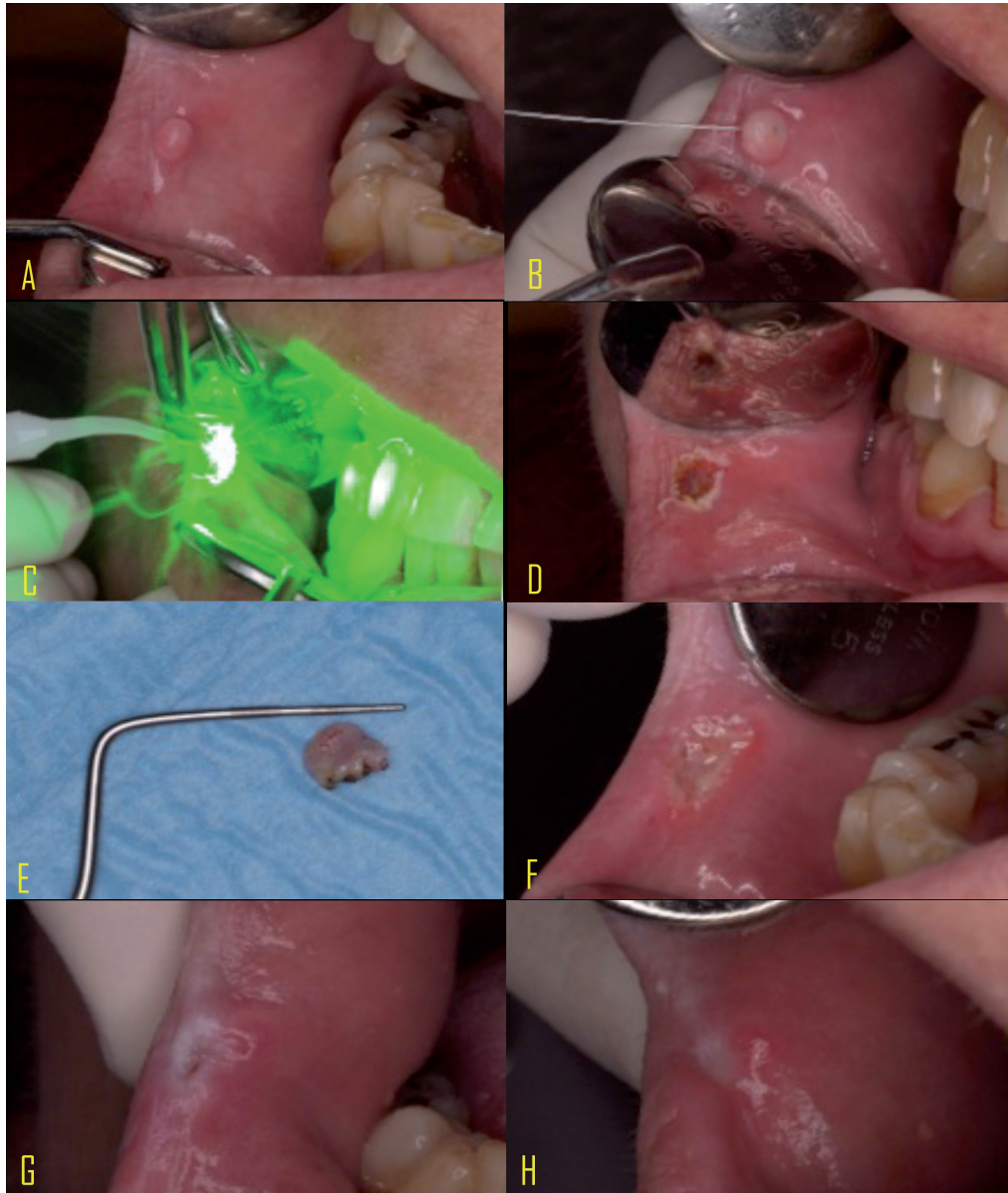

Fig. 2: KTP laser group. A Initial view of lesion; B Anesthesia ; C Excision of the lesion; D Lesion excised; E Immediate follow up; F 24 h follow up; G 14 days follow up; H 28 days follow up.

if they deemed necessary. If they took any medication prescribed or not, the time, the date and the amount had to be indicated in the NDC. Evaluation of postoperative parameters of pain, scarring, inflammation and consumption of drugs were recorded at the day of the surgery, 24 hours after, 14 and 28 days after. The researcher in the NDC had to fill out an evaluation form in an itinerary table.

Statistical analyses were performed using t-test chi-square, Brunner Langer, Mann-Whitney and Fisher Test of SPSS 20.0 (IBM, USA). The level of significance was predetermined as 0.05.

Results

Twenty patients with an hyperplastic lesion in the oral mucosa were operated using a power of 1.5 W continuous wave in strict fiber contact. This data was collated from the literature review, in which the use of continuous waves for such resection indicates the use of lasers at low power (between 1 W and 2 W), whereas in the case of using a higher power (from 3 W) indications dictate it should be used pulsed mode or superpulsed to prevent thermal damage to surrounding tissues, especially with the use of the diode laser (18-20).

Regarding the 532 nm laser, the use of this laser for oral

surgery is recommended to be used in low power 1 W to 1.5 W in continuous wave, obtaining very satisfactory results in surgeries (10,12,21). Studies of *in vitro* and *in vivo* use to determine an exact protocol for the resection of lesions with this type of soft tissue laser have not been developed.

The prevalence of bleeding and suture was the same in The distribution of time values with respect to the laser of 980 nm or 532 nm laser or KTP was similar in both groups ($p = 0.436$, Mann-Whitney).

-Postoperative pain:

On the study results, based on a strictly descriptive view, there is a greater proportion of subjects with mild to moderate pain using laser 980 nm versus 532 nm laser and KTP that is notorious that on the visit 1 (24 hours) . This difference in perception of pain may be related to the greater penetration into the tissue due to the lack of absorption surface of the diode laser 980 nm. At Visit 2 (14 days) they were no significant differences for pain between the two lasers. In the monthly visit (28 days), patients in both groups EVA declare a level of pain that is somewhat higher in the laser group or KTP 532 nm; but always classified in the category of ‘absence’ in any

of the two groups, giving a statistically significant difference in the visit 3 (28 days) ($p = 0.023$) (Table 1).

-Inflammation:

Regarding inflammation, the data suggests that there is great consistency between the development of inflammation in both groups of patients. In the laser of 980 nm, a moderate inflammation occurs in some cases, but it is not statistically significant. Furthermore the Langer Brunner test result confirms that the evolution of inflammation is similar for both approaches ($p = 0.989$) (Table 1).

Scarring:

Regarding healing in the two types of lasers along visits, no differences were detected between the two groups, and in both an acceptable healing. In none of the 20 cases there was infection (Table 2).

-Analgesic consumption:

By assessing the bar chart descriptively, it is observed that at Visit 1 (24 hours) in the laser diode of 980 nm, the consumption of Paracetamol is higher than in the 532 nm laser, but this does not provide statistically significant results. At visit 2 and visit 3, there was no consumption of 1 gram Paracetamol (Table 2).

Table 1: Results for Pain and Inflammation (Infl.).

Día	Total	LASER		p
		980 nm	532 nm	
Day 0 Pain	0,45 cm ± 0,70	0,25 cm ± 0,16	0,65 cm ± 0,96	0,123
24 hours Pain	0,69 cm ± 0,57	0,74 cm ± 0,68	0,63 cm ± 0,47	0,912
14 days pain	0,34 cm ± 0,24	0,28 cm ± 0,27	0,40 cm ± 0,21	0,393
28 days pain	0,22 cm ± 0,23	0,11 cm ± 0,13	0,33 cm ± 0,27	0,035
24 hours Infl.	1,06 cm ± 0,95	0,86 cm ± 0,85	1,26 cm ± 1,06	0,247
14 days infl.	0,29 cm ± 0,25	0,24 cm ± 0,23	0,34 cm ± 0,28	0,529
28 days infl.	0,26 cm ± 0,32	0,11 cm ± 0,10	0,41 cm ± 0,39	0,023

Table 2: Results for scarring and drug consumption.

Day	Scarring N (% acceptable scarring)	Laser		p
		980 nm	532 nm	
1	8 (40)	4 (40)	4 (40)	1
15	1(5)	0 (0)	1 (10)	1
28	0 (0)	0 (0)	0 (0)	1
Total	20(100)	10 (100)	10 (100)	
Day	Paracetamol N (% of paracetamol)	Laser		p
		980 nm	532 nm	
1	7 (35)	4 (40)	3 (30)	1
15	0(0)	0 (0)	0 (0)	1
28	0(0)	0 (0)	0(0)	1
Total	20 (100)	10 (100)	10 (100)	

Discussion

Previous studies have compared the laser with conventional surgery (16,22,23). However, there are no studies comparing the 980-nm diode laser and the 532 nm or KTP laser in oral hyperplastic lesions in the oral mucosa. In the current study pain peaking at 24 hours was observed in the 980 nm group descending from then on. For the rest of the review visits in both groups, the trend is the decline from the first time evaluated (1 day).

In our results, we note that the degree of pain on the VAS scale, the high value does not show any significant difference, so we can conclude that both lasers do not cause severe pain.

Several authors have described the absence of postoperative pain after surgery in the oral mucosa with various types of lasers (24-27).

In the monthly visit (28 days), patients in both groups EVA declare a level of pain that is somewhat higher in the 980 nm group or KTP 532 nm; but always is classified in the category of 'absence' in each groups.

So to be in this category of 'absence', the degree of pain can be admitted, in general, independent of the use of lasers of 980 nm or 532 nm laser, or KTP. This difference at 28 days, which always includes in part the absence of pain, may be due to measurements in VAS Scale, which are marked by the patient manually in the reviews.

In our study, none of the cases presented a retractable scar, in the reviewing at Visit 3 (28 days), as in the works of many authors, the absence of scar is recorded (9,26,28).

Considering the results obtained in our study, it is noteworthy that postoperative pain, (no-light on the VAS scale) without inflammation and with good healing occurs regardless of the laser used. Several authors agree that the postoperative course is very comfortable for patients because it is the result of less swelling and minimal inflammatory response (9,29-31).

This can be explained by the low laser damage produced by adjacent tissues, the lymphatic sealed and the formation of a fibrin clot over the wound to protect it from external irritations as we have shown above to give less pain and decreased risk of postoperative infection (12-18,32).

There are no clinical trials comparing these two types of oral soft tissue laser, however we found a histological study of Romeo *et al.* that compares these two wavelengths, and has somewhat better results for the 532 nm laser and KTP. In the pathological examination both lasers showed a clearly defined zone of necrosis with no statistical difference in size. It confirms that the KTP laser produces less thermal damage depending on the tissue that is involved. Romeo *et al.* concluded that the difference between the two laser in the oral soft tissues was minimal (15).

This clinical trial had some limitations on such factors as pain measurement, being that it is subjective and

influenced by numerous authors due to their culture and place of origin. Therefore VAS was employed, which can be understood by most patients and is reliable and can be reproduced (33-35). The measurement of drug consumption was also performed before the actual ingestion of the medication in order not to influence the results.

Conclusions

The excision of benign hyperplastic tumors in buccal mucosa can be performed very safe and efficient with each laser, the 980 nm diode and the 532 nm KTP, used in the study. Although there is a little physical advantage in superficial absorption in the 532 nm for buccal mucosa the 980 nm works as well in clinically. After completed healing there are no differences visible or reported by patients.

References

- Maiman T. Stimulated optical radiation in ruby. *Nature*. 1960;187:493-4.
- Pick RM, Colvard MD. Current status of lasers in soft tissue dental surgery. *J Periodontol*. 1993;64:589-602.
- Torres-Domingo S, Bagan JV, Jiménez Y, Poveda R, Murillo J, Diaz JM, et al. Benign tumors of the oral mucosa: a study of 300 patients. *Med Oral Patol Oral Cir Bucal*. 2008;13:E161-166.
- Esmeli T, Lozada-Nur F, Epstein J. Common benign oral soft tissue masses. *Dent Clin North Am*. 2005;49:223-240.
- Suliman M. An overview of the use of lasers in general dental practice: 1. Laser physics and tissue interactions. *Dent Update*. 2005;32:228-230,233-234,236.
- Gross AJ, Herrmann TRW. History of lasers. *World J Urol*. 2007;25:217-220.
- Moritz A, Schoop U, Goharkhay K, Schauer P, Doertbudak O, Wernisch J, et al. Treatment of periodontal pockets with a diode laser. *Lasers Surg Med*. 1998;22:302-311.
- Elanchezhian S, Renukadevi R, Vennila K. Comparison of diode laser-assisted surgery and conventional surgery in the management of hereditary ankyloglossia in siblings: a case report with scientific review. *Lasers Med Sci*. 2013;28:7-12.
- Romanos G, Nentwig GH. Diode laser (980 nm) in oral and maxillofacial surgical procedures: clinical observations based on clinical applications. *J Clin Laser Med Surg*. 1999;17:193-197.
- Romeo U, Palaia G, Del Vecchio A, Tenore G, Gambarini G, Gutknecht N, et al. Effects of KTP laser on oral soft tissues. An in vitro study. *Lasers Med Sci*. 2010;25:539-543.
- Zhang C, Wang X, Kinoshita J-I, Zhao B, Toko T, Kimura Y, et al. Effects of KTP laser irradiation, diode laser, and LED on tooth bleaching: a comparative study. *Photomed Laser Surg*. 2007;25:91-95.
- Fornaini C, Rocca JP, Merigo E, Meleti M, Manfredi M, Nam-mour S, et al. Low energy KTP laser in oral soft tissue surgery: A 52 patients clinical study. *Med Oral Patol Oral Cir Bucal*. 2012;17:e287-291.
- Goharkhay K, Moritz A, Wilder-Smith P, Schoop U, Kluger W, Jakolitsch S, et al. Effects on oral soft tissue produced by a diode laser in vitro. *Lasers Surg Med*. 1999;25:401-406.
- Soliman MM, Al Thomali Y, Al Shammrani A, El Gizaerly H. The use of soft tissue diode laser in the treatment of oral hyper pigmentation. *Int J Health Sci (Qassim)*. 2014;8:133-140.
- Romeo U, Russo C, Palaia G, Lo Giudice R, Del Vecchio A, Visca P, et al. Biopsy of different oral soft tissues lesions by KTP and diode laser: histological evaluation. *Scientific World Journal*. 2014;2014:761704.

16. Ize-Iyamu IN, Saheeb BD, Edetanlen BE. Comparing the 810nm diode laser with conventional surgery in orthodontic soft tissue procedures. *Ghana Med J.* 2013;47:107–111.
17. Romeo U, Palaia G, Tenore G, Del Vecchio A, Nammour S. Excision of oral mucocele by different wavelength lasers. *Indian J Dent Res.* 2013;24:211–215.
18. Cercadillo-Ibarguren I, España-Tost A, Arnabat-Domínguez J, Valmaseda-Castellón E, Berini-Aytés L, Gay-Escoda C. Histologic evaluation of thermal damage produced on soft tissues by CO₂, Er,Cr:YSGG and diode lasers. *Med Oral Patol Oral Cir Bucal.* 2010;15:e912–918.
19. Angiero F, Parma L, Crippa R, Benedicenti S. Diode laser (808 nm) applied to oral soft tissue lesions: a retrospective study to assess histopathological diagnosis and evaluate physical damage. *Lasers Med Sci.* 2012;27:383–388.
20. Capodiferro S, Maiorano E, Lojudice AM, Scarpelli F, Favia G. Oral laser surgical pathology: a preliminary study on the clinical advantages of diode laser and on the histopathological features of specimens evaluated by conventional and confocal laser scanning microscopy. *Minerva Stomatol.* 2008;57:1-7.
21. Romeo U, Del Vecchio A, Russo C, Palaia G, Gaimari G, Arnabat-Domínguez J, et al. Laser treatment of 13 benign oral vascular lesions by three different surgical techniques. *Med Oral Patol Oral Cir Bucal.* 2013;18:e279–284.
22. Kravitz ND, Kusnoto B. Soft-tissue lasers in orthodontics: an overview. *Am J Orthod Dentofacial Orthop.* 2008;133:S110–114.
23. Fornaini C, Merigo E, Vescovi P, Lagori G, Rocca J. Use of laser in orthodontics: applications and perspectives. *Laser Ther.* 2013;22:115–124.
24. Strauss RA, Guttenberg SA. Lasers in oral and maxillofacial surgery. *Oral Maxillofac Surg Clin North Am.* 2004;16:XI – XII.
25. Walinski CJ. Irritation fibroma removal: a comparison of two laser wavelengths. *Gen Dent.* 2004;52:236–238.
26. Pie-Sanchez J, España-Tost A, Arnabat-Domínguez J, Gay-Escoda C. Comparative study of upper lip frenectomy with the CO₂ laser versus the Er, Cr:YSGG laser. *Med Oral Patol Oral y Cir Bucal.* 2012;17:e228–232.
27. Pogrel MA. The Carbon dioxide laser in soft tissue preprothetic surgery. *J Prothet Dent.* 1989;61:203–208.
28. Boj JR, Poirier C, Hernandez M, Espassa E, Espanya A. Review: laser soft tissue treatments for paediatric dental patients. *Eur Arch Paediatr Dent.* 2011;12:100–105.
29. Kyzer MD, Aly AS, Davidson JM, Reinisch L, Ossoff RH. Subablation effects of the KTP laser on wound healing. *Lasers Surg Med.* 1993;13:62–71.
30. Romanos GE. Diode laser soft-tissue surgery: advancements aimed at consistent cutting, improved clinical outcomes. *Compend Contin Educ Dent.* 2013;34:752–757.
31. Romeo U, Libotte F, Palaia G, Galanakis A, Gaimari G, Tenore G, et al. Oral soft tissue wound healing after laser surgery with or without a pool of amino acids and sodium hyaluronate: a randomized clinical study. *Photomed Laser Surg.* 2014;32:10–16.
32. Lopez-Jornet P, Camacho-Alonso F. Comparison of pain and swelling after removal of oral leukoplakia with CO₂ laser and cold knife: A randomized clinical trial. *Med Oral Patol Oral y Cir Bucal.* 2013;18:e38–44.
33. Yague-Garcia J, España-Tost AJ, Berini-Aytes L, Gay-Escoda C. Treatment of oral mucocele-scalpel versus CO₂ laser. *Med Oral Patol Oral Cir Bucal.* 2009;14:e469–474.
34. Scott P, Sherriff M, Dibiase AT, Cobourne MT. Perception of discomfort during initial orthodontic tooth alignment using a self-ligating or conventional bracket system: a randomized clinical trial. *Eur J Orthod.* 2008;30:227–232.
35. Sobouti F, Rakhshan V, Chiniforush N, Khatami M. Effects of laser-assisted cosmetic smile lift gingivectomy on postoperative bleeding and pain in fixed orthodontic patients: a controlled clinical trial. *Prog Orthod.* 2014;15:66.

Conflicts of Interest

The authors state that they have no conflicts of interest.