



Contents lists available at ScienceDirect

International Journal of Surgery Case Reports

journal homepage: www.casereports.com

Cribiform variant of papillary thyroid cancer and familial adenomatous polyposis

E. Perea del Pozo^{a,*}, C. Ramirez Plaza^b, J. Padillo Ruiz^c, J.M. Martos Martínez^c^a General and Digestive Surgery Service, University Hospital Virgen del Rocío, Av Manuel Siurot s/n, c/Compas del Porvenir n°3, CP 41013 Seville, Spain^b General and Digestive Surgery Service, Hospital Quirón Málaga, Avenida Imperio Argentina, n° 1, Málaga CP 29004, Spain^c General and Digestive Surgery Service, University Hospital Virgen del Rocío, Av Manuel Siurot s/n, CP 41013 Seville, Spain

ARTICLE INFO

Article history:

Received 27 March 2015

Received in revised form 11 August 2015

Accepted 11 August 2015

Available online 28 August 2015

Keywords:

Familial
Polyposis
Papillary
Cribiform
Thyroid

ABSTRACT

BACKGROUND: Familial adenomatous polyposis (FAP) is an autosomal dominant cancer predisposition syndrome characterised by the progressive development of multiple colorectal adenomatous polyps and an increased incidence of colorectal carcinoma. It is often accompanied by other benign or malignant extracolonic manifestations, including gastric and duodenal tumours, osteomas, desmoid tumours, retinal pigmentation, and thyroid and adrenocortical tumours

METHODS AND RESULTS: We report the case of a 42-year-old white female with FAP who was referred to our Endocrine Surgery Unit for surgery because of a palpable mass in the left side of the neck. An ultrasound-guided fine needle aspiration biopsy showed a cribriform-morular variant (CMV) of papillary thyroid carcinoma (PTC). The incidence, clinical presentation, histology and treatment options for this rare histological subtype are discussed.

CONCLUSIONS: The diagnosis of CMV of PTC is very strongly related to the FAP syndrome and must be suspected when a thyroid node appears in FAP patients. Likewise, any patient without known FAP who presents this histology in a surgically biopsied or resected thyroid node should undergo total colonoscopy for screening of colonic polyposis and genetic study of the APC gene sequence.

© 2015 The Authors. Published by Elsevier Ltd. on behalf of Surgical Associates Ltd. This is an open access article under the CC BY-NC-ND license (<http://creativecommons.org/licenses/by-nc-nd/4.0/>).

1. Introduction

Familial adenomatous polyposis (FAP) is an autosomal dominant cancer predisposition syndrome characterised by the progressive development of multiple colorectal adenomatous polyps and an increased incidence of colorectal carcinoma. It is often accompanied by other benign or malignant extracolonic manifestations, including gastric and duodenal tumours, osteomas, desmoid tumours, retinal pigmentation, and thyroid and adrenocortical tumours [1].

FAP-associated thyroid neoplasms are rare, with a reported incidence of 1–2% in the FAP registries. Most cases of FAP (95–98%) affect women younger than 30 years of age with papillary thyroid carcinoma (PTC). PTC in FAP patients has an increased frequency of the cribriform-morular variant (CMV), an unusual and peculiar histological subtype with morular areas and a multifocal development [2].

We report the case of a patient with a previous diagnosis of FAP who was treated in our Endocrine Surgery Unit for a thyroid mass. The final histological report referred to CMV of PTC. The inci-

dence, clinical presentation, histology and treatment options are also discussed.

2. Case report

A 42-year-old white female with a previous diagnosis of FAP was referred to our Endocrine Surgery Unit to undergo surgery of a palpable mass in the left side of the neck. The ultrasound study revealed a 3.5 cm node in the middle of the left thyroid lobe, with no evidence of cervical, paratracheal or mediastinal lymphadenopathy. The results of a fine needle aspiration biopsy were consistent with PTC (Group 5 according to the Bethesda classification). In relation with her FAP, the patient had undergone a subtotal colectomy, an ampullectomy and resection of a desmoid mesenteric tumour (10, 5 and 3 years, respectively, before the diagnosis of the thyroid tumour). The patient's mother, who had had a nodular goitre, had died of a digestive tumour and her grandmother of a tumour in the cervical region of unknown aetiology.

The patient underwent an elective total thyroidectomy without complications. The final pathologic diagnosis was a multifocal bilateral CMV of PTC, exclusively intrathyroid, with the largest nodule measuring 3.5 cm. Figs. 1 and 2 show the architectural pattern of papillary and grooved nuclei characteristic of PTC, with solid zones containing fusiform cells and the cribriform pattern.

* Corresponding author. Fax: +34 687025522.
E-mail address: eperepo@gmail.com (E. Perea del Pozo).

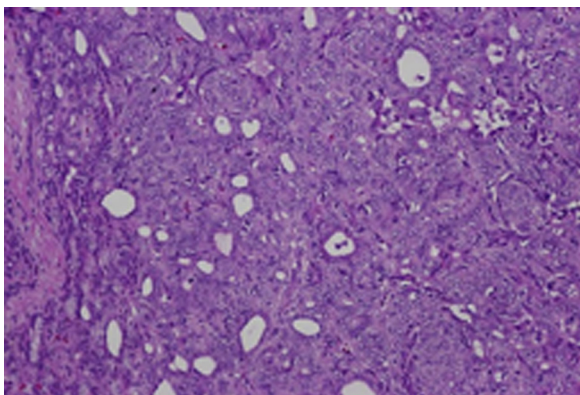


Fig. 1. Architectural pattern of the cribriform-morular variant papillary thyroid carcinoma with solid zones containing spindle cells arranged in spiral and grooved nuclei (Hematoxylin & Eosin; $\times 75$).

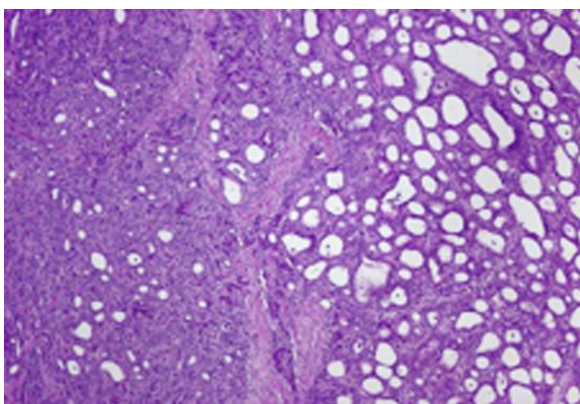


Fig. 2. Microscopic aspect of cribriform lesions of papillary thyroid carcinoma typically found in familial adenomatous polyposis (Hematoxylin & Eosin; $\times 150$).

The immunohistochemical study revealed TTF1 (+), cytokeratin (+) and beta-catenin (+). Postoperatively, the patient was treated with therapeutic radioactive iodine ablation and is currently free of locoregional recurrence 2 years after surgery.

3. Discussion

Many familial syndromes are associated with thyroid neoplasms, including Cowden's disease, Peutz-Jeghers syndrome, ataxia telangiectasia, multiple endocrine neoplasia syndromes and, more recently FAP [3]. FAP is a rare condition (1:10000 persons) transmitted in an autosomal dominant pattern related to germline mutation of the tumour suppressor gene adenomatous polyposis coli (*APC*), which strongly predisposes to colorectal cancer [1]. Thyroid carcinoma rarely coexists with FAP (in just 0.3–1.2% of cases), but when it does it has a very characteristic and unique microscopic pattern, with nearly 100% of cases being CMV of the papillary subtype [4–6]. An exhaustive review of the medical literature has revealed approximately 200 cases since the first description by Crail in 1949 [7]. Nevertheless, CMV is only present in 0.1% of patients with sporadic PTC.

The diagnosis of CMV of PTC linked to AFP requires one or more of the following three features: (a) colonic polyposis detected on total colonoscopy before or after thyroid surgery; (b) presence of *APC* gene mutations; and, (3) family history of colonic polyposis or colorectal carcinoma [7]. CMV of PTC in AFP patients exhibits a typical epidemiology, with a female: male ratio of 17:1 and a mean age of 27.65 years. Compared with women without FAP, the risk of CMV of PTC is 100 times higher, increasing to 160 times higher if only

women under the age of 35 are considered [9,10]. In these circumstances, CMV of PTC can be clearly considered as an extracolonic manifestation of the FAP syndrome and may often be present as early as 4–12 years before colon manifestations.

Macroscopically, CMV of PTC are typically multifocal and have a very low potential to disseminate to regional lymph nodes. Ito et al. compared retrospectively two cohorts of patients with CMV of PTC, FAP-associated ($n = 19$) and sporadic ($n = 12$), and found that 75% of the FAP group had multiple tumours on preoperative ultrasound and 83% had multiplicity on pathological examination (versus 0% and 11%, respectively, for sporadic cases). All the patients in both groups were node negative and none had extrathyroid extension [8]. Iwama and Tomoda reported personal series of 11 and 7 cases, respectively, with no associated deaths and no cases of recurrence [11,12]. These findings explain why the best surgical treatment for CMV of PTC in FAP is total thyroidectomy without the need for prophylactic central node dissection. Studies have reported 5- and 20-year survival rates of 90% and 77%, which can be compared with conventional PTC and suggests an excellent outcome for these patients if treated appropriately and in a timely fashion with regard to both thyroid carcinoma and colon cancer [13].

Microscopically, CMV of PTC presents the distinctive features of papillary neoplasms with a cribriform and morular architecture. The concept of “cribriform” explains the perforated architecture, and “morular” designates the presence of cells in a spindled or whorled pattern forming nest-like structures, like a morule [14]. Frequently, this pattern may be confused with highly aggressive neoplasms, but the lack of nuclear atypia, mitosis and necrosis help in the differential diagnosis. Immunohistochemical studies describe typical cytoplasmic expression of thyroglobulin, neuron-specific enolase, epithelial membrane antigen, low molecular weight cytokeratin, vimentin and protein bc12. Nuclear expression of progesterone and oestrogen has also been described. The expression of retinoblastoma protein and beta-catenin (positive in our case) in the nucleus and cytoplasm, although less frequent, has also been reported in some cases [15].

No consensus exists about the need for systematic screening with cervical ultrasound for thyroid tumours in patients with FAP because of the low prevalence, but it would not seem to be sufficiently cost-effective to justify. Nevertheless, the diagnosis of a CMV of PTC in any patient without FAP is highly suggestive of the familial disease and, accordingly, an indication for total colonoscopy for screening of colonic polyposis and genetic study of the *APC* gene sequence.

Authors contribution

Eduardo Perea del Pozo is the main author of the paper. He had the idea or reporting the case and elaborated the discussion.

César Pablo Ramírez-Plaza is the doctor who diagnosed the disease and has elaborated the clinical case and collected the bibliography.

Padillo Javier Ruiz is the head of General Surgery Service, has reviewed the article and complete the conclusions.

References

- [1] C.R. Sachatello, W.O. Griffen Jr., Hereditary polyposoid diseases of the gastrointestinal tract: a working classification, *Am. J. Surg.* 129 (2) (1975) 198–203.
- [2] J. Cameselle-Teijeiro, J.K. Chan, Cribriform-morular variant of papillary carcinoma: a distinctive variant representing the sporadic counterpart of familial adenomatous polyposis-associated thyroid carcinoma? *Mod. Pathol.* 12 (4) (1999) 400–411.
- [3] F. Cetta, S. Olschwang, M. Petracchi, G. Montalto, C. Baldi, M. Zuckermann, C. Mariani, R. Ostantini, A. Fusco, Genetic alterations in thyroid carcinoma associated with familial adenomatous polyposis: clinical implications and suggestions for early detection, *World J. Surg.* 22 (12) (1998) 1231–1236.

- [4] F.M. Giardiello, G.J. Offerhaus, D.H. Lee, A.J. Krush, A.C. Tersmette, S.V. Booker, N.C. Kelley, S.R. Hamilton, Increased risk of thyroid and pancreatic carcinoma in familial adenomatous polyposis, *Gut* 34 (10) (1993) 1394–1396.
- [5] C. Gronnier, G. Donatini, E. Leteurtre, C. Do Cao, B. Carnaille, Cribriform-morular variant of papillary thyroid carcinoma: characteristic histologic feature of adenomatous polyposis. A case report, *Ann. Endocrinol. (Paris)* 73 (3) (2012) 213–215.
- [6] H.R. Harach, G.T. Williams, E.D. Williams, Familial adenomatous polyposis associated thyroid carcinoma: a distinct type of follicular cell neoplasm, *Histopathology* 25 (6) (1994) 549–561.
- [7] H.W. Crail, Multiple primary malignancies arising in the rectum, brain, and thyroid; report of a case, *U. S. Nav. Med. Bull.* 49 (1) (1949) 123–128.
- [8] Y. Ito, A. Miyauchi, H. Ishikawa, M. Hirokawa, T. Kudo, C. Tomoda, A. Miya, Our experience of treatment of cribriform morular variant of papillary thyroid carcinoma; difference in clinicopathological features of FAP-associated and sporadic patients, *Endocr. J.* 58 (8) (2011) 685–689.
- [9] W.J. Harb, E.M. Sturgis, Differentiated thyroid cancer associated with intestinal polyposis syndromes: a review, *Head Neck* 31 (11) (2009) 1511–1519.
- [10] R.O. Plail, H.J. Bussey, G. Glazer, J.P. Thomson, Adenomatous polyposis: an association with carcinoma of the thyroid, *Br. J. Surg.* 74 (5) (1987) 377–380.
- [11] T. Iwama, Y. Mishima, J. Utsonomiya, The impact of familial adenomatous polyposis on the tumorigenesis and mortality at the several organs. Its rational treatment, *Ann. Surg.* 217 (2) (1993) 101–108.
- [12] C. Tomoda, A. Miyauchi, T. Uruno, Y. Takamura, Y. Ito, A. Miya, K. Kobayashi, F. Matsuzuka, S. Kuma, K. Kuma, K. Kakudo, Cribriform-morular variant of papillary thyroid carcinoma: clue to early detection of familial adenomatous polyposis-associated colon cancer, *World J. Surg.* 28 (9) (2004) 886–889.
- [13] K.A. Donnellan, S.A. Bigler, R.O. Wein, Papillary thyroid carcinoma and familial adenomatous polyposis of the colon, *Am. J. Otolaryngol.* 30 (1) (2009) 58–60.
- [14] S.V. Kane, I.N. Bagwan, Cribriform-morular variant of papillary carcinoma: the sporadic counterpart of familial adenomatous polyposis-associated thyroid carcinoma, *Oral Oncol.* 42 (2006) 167–169.
- [15] B. Xu, K. Yoshimoto, A. Miyauchi, S. Kuma, N. Mizusawa, M. Hirokawa, T. Sano, Cribriform-morular variant of papillary thyroid carcinoma: a pathological and molecular genetic study with evidence of frequent somatic mutations in exon 3 of the beta-catenin gene, *J. Pathol.* 199 (1) (2003) 58–67.

Open Access

This article is published Open Access at scimedirect.com. It is distributed under the [IJSCR Supplemental terms and conditions](#), which permits unrestricted non commercial use, distribution, and reproduction in any medium, provided the original authors and source are credited.