

[Click here to view linked References](#)

This is an Accepted Manuscript of an article published by Springer Nature in Graefe's Archive for Clinical and Experimental Ophthalmology 260 (11) 3437 – 3452, on November 2022, available at: <https://doi.org/10.1007/s00417-022-05728-0>.

Title

Cataract Surgery Astigmatism Incisional Management. Manual Relaxing Incision Versus Femtosecond Laser-Assisted Arcuate Keratotomy. A systematic review.

Authors

Timoteo González-Cruces OD MSc ^{1,2}, Antonio Cano-Ortiz MD ¹, María Carmen Sánchez-González OD PhD ², and José-María Sánchez-González OD PhD ²

¹ Department of Anterior Segment, Cornea and Refractive Surgery, Hospital La Arruzafa, Cordoba, Spain.

² Department of Physics of Condensed Matter, Optics Area. University of Seville, Seville, Spain.

Corresponding Author

José-María Sánchez-González / Reina Mercedes Street. University of Seville, Seville, Spain

+34 618 20 41 10 / jsanchez80@us.es

Key Messages

What is known

49
50
51
52
53
54
55
56
57
58
59
60

- Manual and femtosecond laser corneal relaxing incision are safe and effective in corneal astigmatism correction in cataract surgery

What this paper adds

- Femtosecond laser arcuate keratotomy represent a more precise and predictable approach
- Cost-benefit analysis is controversial since visual and refractive outcomes appear to be similar between manual and femtosecond techniques

61
62
63
64
65

1
2 *Abstract*

3
4 Purpose: This systematic review aims to compare corneal astigmatism correction in cataract surgery
5
6 through corneal relaxing incision, manually and femtosecond laser assisted.

7
8 Methods: The study was performed according to the Preferred Reporting Items for Systematic Reviews and
9
10 Meta-Analyses (PRISMA) statement recommendations. We used PubMed, Scopus, and Web of Science
11
12 (WOS) as databases from January 2010 to March 30, 2021. Patients with keratoconus, corneal ectasia, and
13
14 a previous history of eye surgery were excluded since our aim was to analyze only healthy eyes.

15
16 Results: A total of 1025 eyes were evaluated from 946 patients (mean age was 68.90 ± 5.12) in manual
17
18 incision group articles, while 1905 eyes of 1483 patients (mean age was 65.05 ± 4.57) were evaluated in
19
20 femtosecond laser arcuate keratotomy (FLAK) articles. The mean uncorrected distance visual acuity
21
22 (UDVA) was 0.19 ± 0.12 and 0.15 ± 0.05 logMAR for manual incision and FLAK articles, respectively
23
24 ($p=0.39$). The mean correction index (CI) was similar in both groups: 0.77 ± 0.18 in manual incision and
25
26 0.79 ± 0.17 in femtosecond laser assisted incision ($p=0.70$). Refractive stability was found after three
27
28 months and no serious complications were reported during the follow-up in any group.

29
30 Conclusion: Both techniques are safe and moderate effective in corneal astigmatism correction in cataract
31
32 surgery. FLAK represent a more precise and predictable approach. However, since visual and refractive
33
34 outcomes appear to be similar in both cases, the cost-benefit analysis is controversial.

35
36
37
38
39
40 *Keywords:* opposite clear corneal incision, limbal relaxing incision, femtosecond laser arcuate keratotomy,
41
42 cataract surgery.

43
44 ***Introduction***

45
46 The classic goal of cataract surgery is to achieve acceptable uncorrected distance visual acuity (UDVA)
47
48 after intraocular lens (IOL) implantation. Mean corneal astigmatism in age-related cataract surgery is
49
50 approximately 1 diopters (D).[1] The management of astigmatism during cataract surgery is crucial to
51
52 controlling refractive residual error and achieving greater spectacle independence. Some studies have
53
54 suggested that residual error astigmatism is a main factor in blurred vision and dissatisfaction after
55
56 multifocal and monofocal IOL implantation.[2, 3] Therefore, Schallhorn et al.[4] have suggested that
57
58

1 corneal astigmatism > 0.50 D be considered in surgical planning. Astigmatism correction in these patients
2 can be performed by toric IOL implantation, excimer laser corneal surgery, or steep axis corneal incisions.

3
4 In the mid-1980s, IOL implantation surgery started to be performed with corneal incisions to manage pre-
5 existing astigmatism.[5] This technique is now widely accepted for correcting corneal astigmatism up to 2
6 D[6] and can be performed manually or by femtosecond-laser assistance. There are three different manual
7 incision techniques depending on the location. The limbal relaxing incision (LRI) and the opposite clear
8 corneal incision (OCCI) are performed on the peripheral cornea, and the arcuate keratectomy (AK) is
9 performed more centrally.

10
11 LRIs are non-penetrating incisions made at the corneal periphery for the treatment of corneal astigmatism.
12 Most are placed 1 mm inside the limbus.[7] Several studies have suggested that the LRI is an effective and
13 safe method to reduce corneal astigmatism during cataract surgery up to 3 D.[8] The OCCI, as described
14 by Lever and Dahan,[9] is a modification of the standard coaxial small incision cataract surgery with an
15 additional, identical incision on the opposite side, on the steep corneal axis. Correction of
16 corneal astigmatism induced by the paired OCCI is greater compared to single on-axis incisions.[10] The
17 OCCI has some advantages over the LRI, namely, it is easier to perform, and peripheral pachymetry
18 measurements are not necessary.[11] However, because they are penetrating incisions, they are associated
19 with a greater theoretical risk of endophthalmitis.[12]

20
21 Within the relaxing corneal incision category, an arcuate keratotomy (AK) can also be performed. Since
22 the AK is performed closer to the corneal center (within 7.0–9.0 mm of the optical zone),[13] it has a greater
23 impact on the steeper meridian and induces more change in corneal astigmatism. Femtosecond laser
24 assistance can be used for this procedure, since it can make accurate and precise incisions regardless of the
25 surgeon's experience, a technique known as femtosecond laser arcuate keratotomy (FLAK). Using this
26 technique, a non-penetrating intrastromal incision can be used, which reduces the risk of adverse effects.
27 The main challenge in using FLAK for managing astigmatism is having a suitable nomogram to achieve a
28 satisfactory success rate. In addition, although the safety and effectiveness of femtosecond laser-assisted
29 cataract surgery (FLACS) has been confirmed, its cost-benefit analysis is controversial.[14, 15] The
30 benefits of FLACS are as follows: femtosecond laser capsulotomy is much more accurate[15] and
31 endothelial cell loss is lower than with conventional surgery, reducing the effective phacoemulsification
32 time;[16] the size, alignment, and localization of the corneal incisions are more reproducible;[17] and a
33
34
35
36
37
38
39
40
41
42
43
44
45
46
47
48
49
50
51
52
53
54
55
56
57
58
59
60
61
62
63
64
65

1 multiplanar incision can be performed to improve wound sealing. However, the main drawback is the cost.
2 Additionally, several authors[15, 18] have not found significant statistical differences in visual outcomes
3 between FLACS and conventional phacoemulsification. Kanclerz et al.[15] have suggested that FLACS
4 represents an advantage only to some patient groups, such as those with a low endothelial cell count and
5 those undergoing multifocal IOL implantation. In a recent review, Day et al.[19] also concluded that
6 FLACS was not cost-effective.
7
8
9

10
11
12 The purpose of this review was to determine the best approach to manage astigmatism during cataract
13 surgery by comparing both the manual and femtosecond laser-assisted corneal incision methods.
14
15
16
17

18 **Methods**

19
20
21 This systematic review was performed according to the Preferred Reporting Items for Systematic Reviews
22 and Meta-Analyses (PRISMA)[20] statement recommendations. We used PubMed, Scopus, and Web of
23 Science (WOS) as databases from January 2010 to March 30, 2021. Data search strategy with Boolean
24 operators were: (LRI OR Limbal relaxing incisions OR astigmatic keratotomy OR arcuate keratotomy OR
25 AK OR arcuate incision OR clear corneal incision OR paired opposite clear corneal incision OR OCCI OR
26 on-axis incisions OR paired opposite incision OR femtosecond laser-assisted keratotomy OR femtosecond
27 laser intrastromal astigmatic keratotomy OR Femtosecond Arcuate Keratotomy OR AK-FLACS OR
28 femtosecond laser-assisted astigmatic keratotomy OR Femtosecond laser AK) AND cataract surgery NOT
29 Radial keratotomy NOT RK NOT SMILE NOT small incision lenticule extraction NOT KC NOT
30 Keratoconus NOT ectasia NOT keratoplasty NOT corneal transplantation. Patients with keratoconus,
31 corneal ectasia, and a previous history of eye surgery were excluded since our aim was to analyze only
32 healthy eyes, and, due to alterations in corneal biomechanics, different responses to incisions may occur
33 with both corneal ectatic disorder and a history of previous eye surgeries. All 520 articles retrieved were
34 assessed by one author who selected them according to the inclusion and exclusion criteria. Data collection
35 was performed by two unbiased authors who then verified the duplicates. The included articles were
36 separated into two groups: the manual incision group (group 1) and the femtosecond laser-assisted incision
37 group (group 2). Human studies, full-length original articles, case series, and retrospective and prospective
38 studies with any subjects, duration of follow-up, and outcomes measured were included. The exclusion
39
40
41
42
43
44
45
46
47
48
49
50
51
52
53
54
55
56
57
58

1 criteria were non-English publications, those published in low impact journals, single case reports, biased
2 articles, toric IOL implantations associated with astigmatic corneal incisions, and letters to the editor.

3
4 Data from each study are summarized in Tables 1–2 (design and methods) and Tables 3–4 (results). For
5
6 Tables 1–2, the following information was retrieved from each article: (1) author and date of publication
7
8 (year), (2) study design, (3) mean follow-up time of all patients (expressed in months), (4) number of
9
10 patients, (5) number of eyes involved, (6) information about the sex of the patients (female/male), (7) mean
11
12 age of the patients (years), (8) range of preoperative corneal astigmatism (in Ds), (9) femtosecond laser
13
14 platform (for the FLAK cases), (10) incision depth, (11) incision type, (12) incision number, and (13)
15
16 location of the phacoemulsification incision. For Tables 3–4, the following data were retrieved: (1) author
17
18 and date of publication (year); (2) uncorrected distance visual acuity (UDVA) logarithm of the minimum
19
20 angle of resolution (logMAR) and Snellen notation, pre-and post-surgery; (3) corrected distance visual
21
22 acuity (CDVA) logMAR and Snellen notation, pre- and post-surgery; (4) mean keratometry astigmatism
23
24 (in Ds) pre- and post-surgery; (5) mean refractive astigmatism (in Ds), pre- and post-surgery; (6) target
25
26 induced astigmatism (TIA; in Ds); (7) surgically induced astigmatism (SIA; in Ds); (8) correction index
27
28 (CI); and (9) index of success (IS). Both indices (CI and IS) represented the success of the treatment. CI is
29
30 defined as the magnitude of SIA divided by the magnitude of the TIA. A $CI < 1.0$ indicates an
31
32 undercorrection, a $CI > 1.0$ indicates overcorrection, and a $CI = 1.0$ is ideal. In contrast, to calculate the IS,
33
34 the difference vector (DV) is divided by the TIA, and an IS of zero is ideal. When the TIA value was not
35
36 explicitly reported in the studies, it was completed using the preoperative keratometry astigmatism. All
37
38 means were expressed together with their dispersion values using the standard deviation, range, or
39
40 interquartile range, as reported in the original articles.

41
42
43
44 Analyses were performed using SPSS Statistics Software (version 25, IBM Corp., Armonk, NY, USA).
45
46 The condition of normality of the variables was evaluated using the Shapiro-Wilk test, applying a
47
48 parametric test (Student's *t*-test and one-way ANOVA) or non-parametric test (Mann-Whitney *U*-test) to
49
50 independent samples, according to the nature of the data.

51
52
53 To avoid the risk of bias, two reliable authors created a synopsis table (Table 5-6) based on the Quality
54
55 Assessment Tool for Case Series Studies from the National Heart, Lung, and Blood Institute.[21] When
56
57 disagreements occurred among the two assessors, a third non-blinded assessor decided the matter. The
58
59 questions included in this tool were as follows: (Q1): Is the study oriented to a clear question? (Q2): Were

1 all the patients results taken into account?; (Q3): Was the follow-up complete?; (Q4): Were the same
2 conditions used in surgical treatment?; (Q5): Was the intervention clearly described?; (Q6): Was the
3 duration of follow-up adequate?; (Q7): Were the results described correctly? This assessment did not
4 determine the exclusion of any study. Articles with a high-level risk of bias had a lower weight for data
5 synthesis.
6
7
8
9

10 **Results**

11
12
13
14 A total of 40 articles published between 2010 and 2021 were included in this systematic review. Half (20)
15 of the articles discussed manual corneal incisions, and the other half discussed femtosecond-assisted
16 incisions. The selection process is presented in a flowchart diagram (Figure 1).
17
18
19
20
21
22
23

24 Manual corneal relaxing incision

25
26
27 All included studies regarding manual corneal relaxing incisions were case reports. The mean follow-up,
28 expressed in months, was 3.83 ± 2.12 (range, 1–6 months). Only two articles had a long-term follow-up of
29 36 months.[22][23] A total of 1025 eyes from 946 patients were evaluated. The mean age of the patients
30 was 68.90 ± 5.12 years (range, 58–79 years). The type of corneal incision used to correct the pre-existing
31 corneal astigmatism were as follows: the LRI was used in 13 articles (65%), the OCCI was used in five
32 (25%), and the AK was used in two (10%). All OCCIs were penetrating incisions, while the LRIs were
33 non-penetrating, with an incision depth of 80%–90% of the peripheral corneal pachymetry or up to 600
34 microns. In the AK group, penetrating incisions were made in one study[24] and non-penetrating incisions
35 were performed, to a depth of 95% of the peripheral corneal thickness, in another study[25]. In the LRI
36 group, the nomogram used to achieve the desired astigmatic effect was the modified Gills nomogram (three
37 studies),[22, 26, 27] the Fukuyama nomogram (one study),[28] the Nichamin nomogram (three studies),[7,
38 29, 30] and the Donnenfeld nomogram (five studies).[23, 31–34] In the AK group, one study[25] used the
39 Lindstrom nomogram, and another[24] performed a 30° arc incision systematically. For the studies using
40 OCCIs, the incision length was between 2 and 3.5 mm based on the amount of corneal astigmatism.
41
42
43
44
45
46
47
48
49
50
51
52
53
54
55

56
57 Of the phacoemulsification incisions, eight articles[10, 11, 29, 32–36] used axis incisions, seven used
58 temporal incisions,[7, 23–26, 30, 31] two used both temporal and axis incisions,[22, 27] one article[33]
59

1 used an on- and off-axis incision and another[28] used superior, temporal, and oblique incisions depending
2 on the orientation of the corneal astigmatism. Standard coaxial small incision cataract surgery (C-SICS)
3 was performed in most cases. A bimanual microincision cataract surgery (B-MICS) was performed in only
4 one study,[28] for which a 1.6 mm clear corneal incision was applied.
5
6

7
8 Regarding the CI, all the studies evaluated in this section resulted in a $CI \leq 1.0$ (undercorrection). The
9 average CI value was 0.77 ± 0.18 (range, 0.39–1.0), suggesting that the TIA was greater than the SIA in
10 these studies. In terms of the different incision types, the CI was 0.82 ± 0.13 and 0.69 ± 0.22 for studies
11 using the LRI and OCCI, respectively ($p = 0.17$). In the AK group, the SIA and TIA values were not
12 reported. There was no statistically significant difference between the different nomograms used in the LRI
13 studies ($p = 0.75$). The mean UDVA pre- and post-surgery was 0.70 ± 0.28 and 0.19 ± 0.12 logMAR ($p <$
14 0.01), and the mean CDVA was 0.33 ± 0.19 and 0.16 ± 0.07 logMAR ($p < 0.01$), respectively. The mean
15 keratometric astigmatism was reduced from 1.86 ± 0.53 D to 1.04 ± 0.48 D post-surgery ($p < 0.01$), and the
16 mean refractive astigmatism was reduced from 1.96 ± 0.62 D to 0.98 ± 0.36 D ($p < 0.01$).
17
18

19 Risk of bias assessment was classified into three evidence-level groups. In manual incision group studies
20 with yeses from zero to three: Ouchi et al.,[28] Maedel et al.,[35] Lam et al.,[30] Mohammad-Rabei et
21 al.,[27] Studies with yeses from four to five: Ganekal et al.,[7] Miyata et al.,[37] Lim et al.,[22] Nemeth et
22 al.,[36] Razmjoo et al.,[10] Roberts et al.,[25] Titiyal et al.,[24] Monaco et al.,[23] Eliwa et al.,[32] Roberts
23 et al.,[33] Stanojcic et al.,[34] Finally studies with yeses from six to seven: Fouda et al.,[26] Freitas et
24 al.,[31] Chiam,[11] Leon et al.,[29] and Ren et al.,[38]
25
26
27

28 29 30 31 32 33 34 35 36 37 38 39 40 41 42 43 *Femtosecond assisted corneal relaxing incision* 44 45

46 All included studies regarding femtosecond-assisted corneal relaxing incisions were case reports. The mean
47 follow-up, expressed in months, was 3.11 ± 1.90 , (range, 1–6 months). Only two articles[39][40] had a
48 follow-up time > 6 months (12 and 24 months). A total of 1905 eyes from 1483 patients were evaluated.
49
50 The mean age of the patients was 65.05 ± 4.57 years (range, 53.6–73 years). The type of incision used in
51 almost all the studies was an AK paired opposite incision between 7.5 and 9 mm in diameter. An OCCI
52 was performed in only one study.[41] An anterior penetrating incision was used for nine studies (45%), an
53 intrastromal incision was used for seven (35%), both an anterior penetrating and intrastromal incision was
54 performed in one article (5%), a total penetrating incision was reported in another article (5%), and two
55
56
57
58
59
60
61
62
63
64
65

1 articles (10%) did not report this information. When the incision type was anterior penetrating, the incision
2 depth achieved was approximately 80%–90% of the pachymetry. For most non-penetrating incisions, an
3 intrastromal incision was made with a depth between 20% and 80% of the corneal pachymetry. The main
4 platform femtosecond laser used was Catalys Laser System (Abbott Medical Optics, Inc.), eleven studies
5 (55%), followed LenSx® (Alcon, Fort Worth, Texas, USA), five studies (25%), IntraLase iFS (Abbott
6 Medical Optics, Inc.) two studies (10%), TechnolasVictus SW 2.7 (Bausch & Lomb Inc, Dornach,
7 Germany) one study (5%), and finally LDV Z8, (Ziemer Ophthalmic Systems, Port, Switzerland) one study
8 (5%). A great variety of different nomograms were used: Donnenfeld LRI Nomogram modified, Day
9 Nomogram, Woodcock nomogram, Wang’s et al. Nomogram, Stevens’s nomogram, Nichamin-Woodcock
10 Nomogram modified, standardized Nomogram of single, non-paired LRIs and Wörtz-Gupta™ Formula,
11 Dr. Julian Stevens Nomograms and Castrop femto AK Nomogram.

12 In terms of visual outcomes, an acceptable UDVA/CDVA was found at the end of the postoperative period.
13 For all the studies reporting visual data, the mean UDVA post-operation was 0.15 ± 0.05 logMAR and the
14 mean CDVA was 0.03 ± 0.05 logMAR. There was a reduction in corneal astigmatism from 1.16 ± 0.26 D
15 to 0.64 ± 0.21 D ($p < 0.01$) after surgery. Furthermore, refractive astigmatism decreased from 1.41 ± 0.17
16 D to 0.57 ± 0.22 D ($p < 0.01$). The mean magnitude of the TIA was 1.16 ± 0.24 D, while the mean SIA was
17 0.94 ± 0.31 D. Most of the studies analyzed obtained an undercorrection result with a mean CI of 0.79 ± 0.17
18 (range, 0.53–1.0). For the articles in which intrastromal incisions were made, the average CI was $0.72 \pm$
19 0.06 , while it was 0.86 ± 0.06 for the articles in which penetrating incisions were made, with no significant
20 differences between the groups ($p = 0.13$). The mean index of success reported was 0.60 ± 0.19 (range,
21 0.20–0.93).

22 In FLAK incision group studies risk of bias assessment was classified into three evidence-level groups with
23 yeses from zero to three: Lee et al.[42] Studies with yeses from four to five: Yoo et al.,[43] Day et al.,[44]
24 Baharozian et al.,[45] Blehm et al.,[46] Löffler et al.,[13] Byun et al.,[47] Roberts et al.,[33] Visco et al.,[48]
25 Chen et al.,[41] Rani et al.,[49] Wortz et al.,[50] and Schwarzenbacher et al.[40] Finally studies with yeses
26 from six to seven: Rückl et al.,[51] Day et al.,[52] Day et al.,[53] Ganesh et al.,[54] and Lim et al.,[55]
27 Moon et al.,[56] and Wendelstein et al.[39]

28 **Discussion**

1
2
3
4
5
6
7
8
9
10
11
12
13
14
15
16
17
18
19
20
21
22
23
24
25
26
27
28
29
30
31
32
33
34
35
36
37
38
39
40
41
42
43
44
45
46
47
48
49
50
51
52
53
54
55
56
57
58
59
60
61
62
63
64
65

Corneal relaxing incisions are one of the most widely-used methods for astigmatism correction during cataract surgery. This method is intended to reduce corneal astigmatism through a flattening effect on the steep meridian and a steepening effect on the flat meridian. Currently, the correction of preexisting astigmatism through corneal incisions can be performed manually or by femtosecond laser assistance, though the benefits and drawbacks of each technique must be considered.

Visual and refractive outcomes

The goal of relaxing corneal incisions during cataract surgery is to achieve acceptable UDVA and spectacle independence. In the articles included in this review, similar visual outcomes were found for manual and femtosecond-assisted incisions. The mean UDVA at the end of the follow up period was 0.19 ± 0.12 and 0.15 ± 0.05 logMAR for manual incisions and for those using FLAK, respectively ($p = 0.39$). All studies achieved a reduction in preexisting corneal astigmatism, although most were undercorrected, regardless of the incision type and nomogram used. A slight undercorrection is always more desirable than an overcorrection because a residual astigmatism on the same axis is better tolerated than that on the opposite axis.[45] Additionally, the mean CI was similar for both groups. In the manual incision group, the mean CI was 0.77 ± 0.18 while in the FLAK group, it was 0.79 ± 0.17 ($p = 0.70$). However, Roberts et al.,[33] in a comparative study, found a greater CI in the femtosecond laser-assisted group 0.73 ± 0.49 compared to the manual incision group (0.48 ± 0.57). In addition, in this study, FLAK was much more accurate than manual incisions for target correction since the use of a target correction of 70% of total preoperative corneal astigmatism (TIA). In the FLAK studies, although no statistically significant differences were found between penetrating incisions and intrastromal incisions, Ganesh et al.[54] reported worse results for the latter. In this study, a more significant undercorrection was reported at 6 months in the intrastromal incision group compared with the penetrating incision group with a CI of 0.55 and 0.95, respectively. Considering the type of preoperative astigmatism, however, Baharozian et al.[45] found a greater tendency toward overcorrection (CI=1.01; 18.6% with 150% of intended correction) in the against-the-rule (ATR) preoperative corneal astigmatism group compared with a systematic undercorrection (CI=0.53) in the with-the-rule (WTR) group using the modified FLAK Donnenfeld nomogram. Similarly, Lim et al.[55] found, in their multivariable analysis, an association between overcorrection and ATR astigmatism using an arcuate femtosecond single laser-assisted LRI. However, Day et al.[52] reported a greater SIA value (0.13 D) in WTR compared to ATR astigmatism using a personal intrastromal AK nomogram.[53]

1 For the manual relaxing incision, Chiam et al.[11] reported a greater effect in WTR compared to ATR
2 astigmatism when an OCCI of the same size was achieved. This is an expected result because the vertical
3 incisions are closer to the visual axis, suggesting a greater effect.[57] However, Nemeth et al.[36] found no
4 significant change in SIA according to the location of the incision when the OCCI was used.
5
6

7
8 Regarding the LRI method, Lim et al.[22] found a slightly higher SIA for ATR compared to WTR
9 astigmatism using the modified Gills nomogram.[58] However, the differences between the two groups
10 were not assessed statistically.
11
12

13 Stability

14
15
16 A regression of the effect of the incisions over time as a result of the wound healing process is a well-
17 known phenomenon.[59] However, it is believed that this regression occurs during the first three months
18 and then remains stable over time.[23, 58] Lim et al.[22] found a statistically significant decrease in SIA
19 from 2 to 10 weeks after the LRI, which remained stable over the three subsequent years. Chiam et al.[11]
20 reported refractive stability six months after performing the OCCI and the SIA remained more stable in
21 WTR compared to ATR astigmatism.
22
23
24
25
26
27
28

29
30 With regard to femtosecond AK, Byun et al.[47] found no difference in keratometric astigmatism between
31 the 2-month follow-up and the final follow-up of 6 months. These results were similar to those reported by
32 Cham et al.,[60] who reported stability in keratometric astigmatism from the 2-month to the 2-year follow-
33 up. This suggests that the results obtained at 2 months are a good indicator of long-term success and would
34 be sufficient to justify a short follow-up period.[46]
35
36
37
38
39
40
41
42
43
44
45
46
47
48
49

50 Complications

51 *Manual relaxing incision*

52
53 LRI is considered one of the safest surgical techniques available for the treatment of corneal astigmatism
54 during cataract surgery, with low risks of intra and postoperative complications.[61] Cases of perforation,
55 incision gaping and glare[58] have been described, although the main complications associated with this
56
57
58
59
60
61
62
63
64
65

1 type of technique are related to keratitis during wound healing, mild epitheliopathy, and dry eye.[62] In the
2 case of the OCCI, there is a greater risk of serious complications, such as wound leak and endophthalmitis,
3 since it involves two paired penetrating incisions.[63] AK is the type of manual incision most likely to lead
4 to adverse visual effects because of its proximity to the visual axis. Other complications have been
5 described, such as microbial keratitis, endophthalmitis, epithelial ingrowth and corneal ectasia.
6
7

8
9
10 The studies included in this review did not describe any serious complications throughout the follow-up
11 period. Eliwa et al.[32] reported foreign body sensations and tearing in 43.48% (10/23) of the patients
12 treated with relaxing incisions. These symptoms were also found in the control cases, although to a lesser
13 extent (22.73%; 5/22), and for a shorter time. Fouda et al.[26] had to suture one of the eyes (5%; 1/20) due
14 to overcorrection, successfully reversing the result. In the report by Ouchi et al.,[28] one patient experienced
15 a rupture of the posterior capsule, which required the insertion of another IOL and wound suturing (0.5%;
16 1/192).
17
18

19
20
21 Only three studies [23, 26, 38] analyze corneal aberration changes. Fouda et al. [26] achieved that LRI
22 induces less high order aberration (HOA) spherical aberration accentuation than three-months post-
23 astigmatic keratectomy. Ren et al.[38] found that root mean square values of corneal trefoil, spherical
24 aberration and total high order aberration (HOA) slightly increase without statistically significant
25 differences. Finally, Monaco & Scialdone [23] were according to Ren et al.[38] results and propose LRI as
26 a viable option when toric IOLs were contraindicated.
27
28
29

30 31 32 33 34 35 36 37 38 39 40 41 *Femtosecond-assisted arcuate keratotomy*

42
43
44 Laser-assisted femtosecond surgery has the advantage of eliminating complications related to
45 inexperienced surgeons making manual incisions. However, other types of complications inherent in
46 femtosecond laser surgery may include gas breakthroughs,[64] inadvertent placement of the AK within the
47 visual axis, a gape in the wound, or suction loss.[51] In addition, energy from the femtosecond laser can
48 cause damage to endothelial cells,[65] although some authors[51] have not reported loss of endothelial
49 cells after AK with femtosecond laser assistance. Kankariya et al.[64] reported a case of anterior gas
50 breakthrough that generated irregular astigmatism and an important overcorrection of corneal astigmatism.
51
52
53
54
55
56
57
58
59
60
61
62
63
64
65

1
2
3
4
5
6
7
8
9
10
11
12
13
14
15
16
17
18
19
20
21
22
23
24
25
26
27
28
29
30
31
32
33
34
35
36
37
38
39
40
41
42
43
44
45
46
47
48
49
50
51
52
53
54
55
56
57
58
59
60
61
62
63
64
65

None of the studies included in this review reported serious complications associated with AK. However, mild adverse effects have been reported. Rani et al.[49] reported a corneal perforation in a patient during keratotomy without any serious consequences. Roberts et al.[33] had some adverse effects related to laser delivery, such as corneal abrasion in 2 cases (3.7%) and incomplete capsulotomy in 3 cases (5.6%). In addition, 2 patients had postoperative cystoid macular edema. Löffler et al.[13] found dry eye symptoms and foreign body sensations in a few patients in the early postoperative period. Rückl et al.[51] reported suction loss due to a patient's inadvertent movement, which caused a slight misalignment of the incision.

Intrastromal incisions in which the epithelium and endothelium are not damaged could be an advantage over penetrating incisions, where there is a greater risk of complications such as perforation, wound gape, and infection.[51] None of the articles included in the Femtosecond group discuss aberrations. Therefore, comparison between both groups was not possible.

In short, although complications inherent to the use of the femtosecond laser technology exist, FLAKs provide greater precision and reproducibility in the depth, length, angulation, and centrality of the incision.[67] In addition, greater control over the shape of the incision could improve postoperative sealing of the wound.[12] The use of FLAK also reduces the risk of incision misalignment due to eye blockage during the incision.[68]

Limitations and Strengths

To the best of our knowledge, this is the first systematic review to compare the corneal incision techniques (manual and femtosecond laser-assisted) used for the management of astigmatism during cataract surgery. Recent articles published in high-impact journals have also been included. There was equal representation for each of the approaches (50%, manual incision; 50%, FLAK). However, some limitations should be considered. Only articles published in English were evaluated. There was also great variability between the studies in the outcomes reported and in the vector analysis of astigmatism. In some cases, follow-up was insufficient. In addition, many variables are involved in the correction of astigmatism through corneal incisions that cannot be compared in isolation. Standard Alpins method astigmatism vector analysis was absence. Therefore, we should improve our understanding of the factors involved in curvature changes after corneal incisions and thus develop more predictable nomograms. Further randomized clinical trials with a

1
2
3
4
5
6
7
8
9
10
11
12
13
14
15
16
17
18
19
20
21
22
23
24
25
26
27
28
29
30
31
32
33
34
35
36
37
38
39
40
41
42
43
44
45
46
47
48
49
50
51
52
53
54
55
56
57
58
59
60
61
62
63
64
65

long follow-up period are necessary to determine which of these approaches is superior. As a future research line, we propose to compare this results with toric IOL.

Conclusion

The safety and moderate effectiveness of manual and femtosecond laser-assisted corneal incisions have been confirmed for astigmatism correction during cataract surgery. FLAKs represent greater precision and predictability in the performance of corneal incisions and allow for the standardization of nomograms. However, since visual and refractive outcomes appear to be similar in both cases, the cost-benefit analysis is controversial.

Compliance with Ethical Standards:

Funding: No funding was received for this research.

Conflict of Interest: All authors certify that they have no affiliations with or involvement in any organization or entity with any financial interest (such as honoraria; educational grants; participation in speakers' bureaus; membership, employment, consultancies, stock ownership, or other equity interest; and expert testimony or patent-licensing arrangements), or non-financial interest (such as personal or professional relationships, affiliations, knowledge or beliefs) in the subject matter or materials discussed in this manuscript.

Ethical approval: This article does not contain any studies with human participants or animals performed by any of the authors.

References

1. Arriola-Villalobos P, Burgos-Blasco B, Fernández-Vigo JI, et al (2021) Biometry data and prevalence of corneal astigmatism in caucasian spanish candidates for cataract surgery. *J Fr Ophthalmol* 44:76–83. <https://doi.org/10.1016/j.jfo.2020.03.025>
2. Berdahl JP, Hardten DR, Kramer BA, Potvin R (2018) Effect of astigmatism on visual acuity after multifocal versus monofocal intraocular lens implantation. *J Cataract Refract Surg* 44:1192–1197. <https://doi.org/10.1016/j.jcrs.2018.06.048>
3. Mayer WJ, Kreutzer T, Dirisamer M, et al (2017) Comparison of visual outcomes, alignment accuracy, and surgical time between 2 methods of corneal marking for toric intraocular lens implantation. *J Cataract Refract Surg* 43:1281–1286. <https://doi.org/10.1016/j.jcrs.2017.07.030>
4. Schallhorn SC, Hettinger KA, Pelouskova M, et al (2021) Effect of residual astigmatism on uncorrected visual acuity and patient satisfaction in pseudophakic patients. *J Cataract Refract Surg* 47:991–998. <https://doi.org/10.1097/j.jcrs.0000000000000560>
5. Osher RH (1989) Paired transverse relaxing keratotomy: A combined technique for reducing astigmatism. *J Cataract Refract Surg* 15:32–37. [https://doi.org/10.1016/S0886-3350\(89\)80137-3](https://doi.org/10.1016/S0886-3350(89)80137-3)
6. Lake JC, Victor G, Clare G, et al (2019) Toric intraocular lens versus limbal relaxing incisions for corneal astigmatism after phacoemulsification. *Cochrane Database Syst Rev* 2019:. <https://doi.org/10.1002/14651858.CD012801.pub2>
7. Ganekal S, Dorairaj S, Jhanji V (2011) Limbal relaxing incisions during phacoemulsification: 6-month results. *J. Cataract Refract. Surg.* 37:2081–2082
8. Ravikumar DK, M DA, Rajakumari DR (2017) A study on efficacy of limbal relaxing incisions in correcting corneal astigmatism along with clear corneal phacoemulsification in a tertiary eye care centre in South India. *Int J Med Res Rev* 5:168–175. <https://doi.org/10.17511/ijmrr.2017.i02.12>
9. Lever J, Dahan E (2000) Opposite clear corneal incisions to correct pre-existing astigmatism in cataract surgery. *J Cataract Refract Surg* 26:803–805. [https://doi.org/10.1016/S0886-3350\(00\)00378-3](https://doi.org/10.1016/S0886-3350(00)00378-3)
10. Peyman A, Rahimi B, Razmjoo H, et al (2014) Corneal astigmatism change and wavefront

aberration evaluation after cataract surgery: “Single” versus “paired opposite” clear corneal incisions. *Adv Biomed Res* 3:163. <https://doi.org/10.4103/2277-9175.139126>

11. Chiam PJ (2015) Effect of Paired Opposite Clear Corneal Incisions on With-the-Rule Versus Against-the-Rule Astigmatism. *Cornea* 34:901–905. <https://doi.org/10.1097/ICO.0000000000000441>
12. Al Mahmood AM, Al-Swailem SA, Behrens A (2014) Clear corneal incision in cataract surgery. *Middle East Afr J Ophthalmol* 21:25–31. <https://doi.org/10.4103/0974-9233.124084>
13. Löffler F, Böhm M, Herzog M, et al (2017) Tomographic Analysis of Anterior and Posterior and Total Corneal Refractive Power Changes After Femtosecond Laser–Assisted Keratotomy. *Am J Ophthalmol* 180:102–109. <https://doi.org/10.1016/j.ajo.2017.05.015>
14. Kolb CM, Shajari M, Mathys L, et al (2020) Comparison of femtosecond laser-assisted cataract surgery and conventional cataract surgery: A meta-analysis and systematic review. *J Cataract Refract Surg* 46:1075–1085. <https://doi.org/10.1097/j.jcrs.0000000000000228>
15. Kanclerz P, Alio JL (2021) The benefits and drawbacks of femtosecond laser-assisted cataract surgery. *Eur J Ophthalmol* 31:1021–1030. <https://doi.org/10.1177/1120672120922448>
16. Ye Z, Li Z, He S (2017) A Meta-Analysis Comparing Postoperative Complications and Outcomes of Femtosecond Laser-Assisted Cataract Surgery versus Conventional Phacoemulsification for Cataract. *J Ophthalmol* 2017:1–7. <https://doi.org/10.1155/2017/3849152>
17. Alió JL, Abdou AA, Soria F, et al (2013) Femtosecond laser cataract incision morphology and corneal higher-order aberration analysis. *J Refract Surg* 29:590–595. <https://doi.org/10.3928/1081597X-20130819-01>
18. Berk TA, Schlenker MB, Campos-Möller X, et al (2018) Visual and Refractive Outcomes in Manual versus Femtosecond Laser–Assisted Cataract Surgery: A Single-Center Retrospective Cohort Analysis of 1838 Eyes. *Ophthalmology* 125:1172–1180. <https://doi.org/10.1016/j.ophtha.2018.01.028>
19. Day AC, Burr JM, Bennett K, et al (2021) Femtosecond laser-assisted cataract surgery compared with phacoemulsification: The FACT non-inferiority RCT. *Health Technol Assess (Rockv)* 25:a-

94. <https://doi.org/10.3310/HTA25060>

- 1
2
3
4
5
6
7
8
9
10
11
12
13
14
15
16
17
18
19
20
21
22
23
24
25
26
27
28
29
30
31
32
33
34
35
36
37
38
39
40
41
42
43
44
45
46
47
48
49
50
51
52
53
54
55
56
57
58
59
60
61
62
63
64
65
20. Liberati A, Altman DG, Tetzlaff J, et al (2009) The PRISMA statement for reporting systematic reviews and meta-analyses of studies that evaluate health care interventions: Explanation and elaboration. *PLoS Med* 6:e1000100. <https://doi.org/10.1371/journal.pmed.1000100>
21. National Institute of Health (2021) National Heart Lung and Blood Institute. Study Quality Assessment Tools. In: <https://www.nhlbi.nih.gov/health-topics/study-quality-assessment-tools>
22. Lim R, Borasio E, Ilari L (2014) Long-term stability of keratometric astigmatism after limbal relaxing incisions. *J Cataract Refract Surg* 40:1676–1681. <https://doi.org/10.1016/j.jcrs.2014.01.045>
23. Monaco G, Scialdone A (2015) Long-term outcomes of limbal relaxing incisions during cataract surgery: aberrometric analysis. *Clin Ophthalmol* 9:1581. <https://doi.org/10.2147/OPTH.S89024>
24. Titiyal JS, Khatik M, Sharma N, et al (2014) Toric intraocular lens implantation versus astigmatic keratotomy to correct astigmatism during phacoemulsification. *J Cataract Refract Surg* 40:741–747. <https://doi.org/10.1016/j.jcrs.2013.10.036>
25. Roberts T V., Sharwood P, Hodge C, et al (2014) Comparison of Toric Intraocular Lenses and Arcuate Corneal Relaxing Incisions to Correct Moderate to High Astigmatism in Cataract Surgery. *Asia-Pacific J Ophthalmol* 3:9–16. <https://doi.org/10.1097/apo.0b013e3182a0af21>
26. Fouda S, Kamiya K, Aizawa D, Shimizu K (2010) Limbal relaxing incision during cataract extraction versus photoastigmatic keratectomy after cataract extraction in controlling pre-existing corneal astigmatism. *Graefe's Arch Clin Exp Ophthalmol* 248:1029–1035. <https://doi.org/10.1007/s00417-009-1272-6>
27. Mohammad-Rabei H, Mohammad-Rabei E, Espandar G, et al (2016) Three methods for correction of astigmatism during phacoemulsification. *J Ophthalmic Vis Res* 11:162–167. <https://doi.org/10.4103/2008-322X.183924>
28. Ouchi M, Kinoshita S (2010) Prospective randomized trial of limbal relaxing incisions combined with microincision cataract surgery. *J Refract Surg* 26:594–599.

<https://doi.org/10.3928/1081597X-20091015-01>

- 1
2
3
4
5
6
7
8
9
10
11
12
13
14
15
16
17
18
19
20
21
22
23
24
25
26
27
28
29
30
31
32
33
34
35
36
37
38
39
40
41
42
43
44
45
46
47
48
49
50
51
52
53
54
55
56
57
58
59
60
61
62
63
64
65
29. Leon P, Pastore MR, Zanei A, et al (2015) Correction of low corneal astigmatism in cataract surgery. *Int J Ophthalmol* 8:719–724. <https://doi.org/10.3980/j.issn.2222-3959.2015.04.14>
30. Lam DKT, Chow VWS, Ye C, et al (2016) Comparative evaluation of aspheric toric intraocular lens implantation and limbal relaxing incisions in eyes with cataracts and ≤ 3 dioptres of astigmatism. *Br J Ophthalmol* 100:258–262. <https://doi.org/10.1136/bjophthalmol-2014-306587>
31. Freitas GO, Boteon JE, Carvalho MJ, Pinto RMC (2014) Treatment of astigmatism during phacoemulsification. *Arq Bras Oftalmol* 77:40–46. <https://doi.org/10.5935/0004-2749.20140011>
32. Eliwa TF, Abdellatif MK, Hamza II (2016) Effect of limbal relaxing incisions on corneal aberrations. *J Refract Surg* 32:156–162. <https://doi.org/10.3928/1081597X-20160121-02>
33. Roberts HW, Wagh VK, Sullivan DL, et al (2018) Refractive outcomes after limbal relaxing incisions or femtosecond laser arcuate keratotomy to manage corneal astigmatism at the time of cataract surgery. *J Cataract Refract Surg* 44:955–963. <https://doi.org/10.1016/j.jcrs.2018.05.027>
34. Stanojcic N, Roberts H, Wagh V, et al (2020) A randomised, prospective study of ‘off-the-shelf’ use of toric intraocular lenses for cataract patients with pre-existing corneal astigmatism in the NHS. *Eye* 34:1809–1819. <https://doi.org/10.1038/s41433-020-0919-8>
35. Maedel S, Hirschall N, Chen YA, Findl O (2014) Rotational performance and corneal astigmatism correction during cataract surgery: Aspheric toric intraocular lens versus aspheric nontoric intraocular lens with opposite clear corneal incision. *J Cataract Refract Surg* 40:1355–1362. <https://doi.org/10.1016/j.jcrs.2013.11.039>
36. Nemeth G, Kolozsvari B, Berta A, Modis L (2014) Paired opposite clear corneal incision: Time-related changes of its effect and factors on which those changes depend. *Eur J Ophthalmol* 24:676–681. <https://doi.org/10.5301/ejo.5000428>
37. Miyata K, Miyai T, Minami K, et al (2011) Limbal relaxing incisions using a reference point and corneal topography for intraoperative identification of the steepest meridian. *J Refract Surg* 27:339–344. <https://doi.org/10.3928/1081597X-20101005-02>
38. Ren Y, Fang X, Fang A, et al (2019) Phacoemulsification With 3.0 and 2.0 mm Opposite Clear

Corneal Incisions for Correction of Corneal Astigmatism. *Cornea* 38:1105–1110.

<https://doi.org/10.1097/ICO.0000000000001915>

39. Wendelstein JA, Hoffmann PC, Mariacher S, et al (2021) Precision and refractive predictability of a new nomogram for femtosecond laser-assisted corneal arcuate incisions. *Acta Ophthalmol* 99:e1297–e1306. <https://doi.org/10.1111/aos.14837>
40. Schwarzenbacher L, Schartmüller D, Röggl V, et al (2021) One-Year Results of Arcuate Keratotomy in Patients With Low to Moderate Corneal Astigmatism Using a Low-Pulse-Energy Femtosecond Laser. *Am J Ophthalmol* 224:53–65. <https://doi.org/10.1016/j.ajo.2020.11.018>
41. Chen W, Ji M, Wu J, et al (2020) Effect of femtosecond laser-assisted steepest-meridian clear corneal incisions on preexisting corneal regular astigmatism at the time of cataract surgery. *Int J Ophthalmol* 13:1895–1900. <https://doi.org/10.18240/ijo.2020.12.08>
42. Lee JA, Song WK, Kim JY, et al (2019) Femtosecond laser–assisted cataract surgery versus conventional phacoemulsification: Refractive and aberrometric outcomes with a diffractive multifocal intraocular lens. *J Cataract Refract Surg* 45:21–27. <https://doi.org/10.1016/j.jcrs.2018.08.032>
43. Yoo A, Yun S, Kim JY, et al (2015) Femtosecond laser-assisted arcuate keratotomy versus toric IOL implantation for correcting astigmatism. *J Refract Surg* 31:574–578. <https://doi.org/10.3928/1081597X-20150820-01>
44. Day AC, Stevens JD (2016) Stability of keratometric astigmatism after non-penetrating femtosecond laser intrastromal astigmatic keratotomy performed during laser cataract surgery. *J Refract Surg* 32:152–155. <https://doi.org/10.3928/1081597X-20160204-01>
45. Baharozian CJ, Song C, Hatch KM, Talamo JH (2017) A novel nomogram for the treatment of astigmatism with femtosecond-laser arcuate incisions at the time of cataract surgery. *Clin Ophthalmol* 11:1841–1848. <https://doi.org/10.2147/OPTH.S141255>
46. Blehm C, Potvin R (2017) Pseudophakic astigmatism reduction with femtosecond laser-assisted corneal arcuate incisions: A pilot study. *Clin Ophthalmol* 11:201–207. <https://doi.org/10.2147/OPTH.S127279>

- 1
2
3
4
5
6
7
8
9
10
11
12
13
14
15
16
17
18
19
20
21
22
23
24
25
26
27
28
29
30
31
32
33
34
35
36
37
38
39
40
41
42
43
44
45
46
47
48
49
50
51
52
53
54
55
56
57
58
59
60
61
62
63
64
65
47. Byun YS, Kim S, Lazo MZ, et al (2018) Astigmatic correction by intrastromal astigmatic keratotomy during femtosecond laser–assisted cataract surgery: Factors in outcomes. *J Cataract Refract Surg* 44:202–208. <https://doi.org/10.1016/j.jcrs.2017.11.018>
 48. Visco DM, Bedi R, Packer M (2019) Femtosecond laser–assisted arcuate keratotomy at the time of cataract surgery for the management of preexisting astigmatism. *J Cataract Refract Surg* 45:1762–1769. <https://doi.org/10.1016/j.jcrs.2019.08.002>
 49. Rani K, Grover A, Singh A, et al (2020) Correction of preexisting astigmatism by penetrating arcuate keratotomy in femtosecond laser-assisted cataract surgery. *Indian J Ophthalmol* 68:1569–1572. https://doi.org/10.4103/ij.o.IJO_2060_19
 50. Wortz G, Gupta PK, Goernert P, et al (2020) Outcomes of femtosecond laser arcuate incisions in the treatment of low corneal astigmatism. *Clin Ophthalmol* 14:2229–2236. <https://doi.org/10.2147/OPTH.S264370>
 51. Rückl T, Dexl AK, Bachernegg A, et al (2013) Femtosecond laser-assisted intrastromal arcuate keratotomy to reduce corneal astigmatism. *J Cataract Refract Surg* 39:528–538. <https://doi.org/10.1016/j.jcrs.2012.10.043>
 52. Day AC, Stevens JD (2016) Predictors of femtosecond laser intrastromal astigmatic keratotomy efficacy for astigmatism management in cataract surgery. *J Cataract Refract Surg* 42:251–257. <https://doi.org/10.1016/j.jcrs.2015.09.028>
 53. Day AC, Lau NM, Stevens JD (2016) Nonpenetrating femtosecond laser intrastromal astigmatic keratotomy in eyes having cataract surgery. *J Cataract Refract Surg* 42:102–109. <https://doi.org/10.1016/j.jcrs.2015.07.045>
 54. Ganesh S, Brar S, Reddy Arra R (2020) Comparison of astigmatism correction between anterior penetrating and intrastromal arcuate incisions in eyes undergoing femtosecond laser-assisted cataract surgery. *J Cataract Refract Surg* 46:394–402. <https://doi.org/10.1097/j.jcrs.0000000000000069>
 55. Lim CW, Somani S, Chiu HH, et al (2020) Astigmatic outcomes of single, non-paired intrastromal limbal relaxing incisions during femtosecond laser-assisted cataract surgery based on a custom nomogram. *Clin Ophthalmol* 14:1059–1070. <https://doi.org/10.2147/OPTH.S238016>

- 1
2
3
4
5
6
7
8
9
10
11
12
13
14
15
16
17
18
19
20
21
22
23
24
25
26
27
28
29
30
31
32
33
34
35
36
37
38
39
40
41
42
43
44
45
46
47
48
49
50
51
52
53
54
55
56
57
58
59
60
61
62
63
64
65
56. Moon SY, Chung HS, Lee JH, et al (2021) Evaluation of Astigmatic Correction Using Vector Analysis after Combined Femtosecond Laser-Assisted Phacoemulsification and Intrastromal Arcuate Keratotomy. *J Ophthalmol* 2021:1–8. <https://doi.org/10.1155/2021/2860840>
 57. Merriam JC, Zheng L, Merriam JE, et al (2003) The effect of incisions for cataract on corneal curvature. *Ophthalmology* 110:1807–1813. [https://doi.org/10.1016/S0161-6420\(03\)00537-2](https://doi.org/10.1016/S0161-6420(03)00537-2)
 58. Budak K, Yilmaz G, Aslan BS, Duman S (2001) Limbal relaxing incisions in congenital astigmatism: 6 month follow-up. *J Cataract Refract Surg* 27:715–719. [https://doi.org/10.1016/S0886-3350\(00\)00687-8](https://doi.org/10.1016/S0886-3350(00)00687-8)
 59. Mingo-Botín D, Muñoz-Negrete FJ, Won Kim HR, et al (2010) Comparison of toric intraocular lenses and peripheral corneal relaxing incisions to treat astigmatism during cataract surgery. *J Cataract Refract Surg* 36:1700–1708. <https://doi.org/10.1016/j.jcrs.2010.04.043>
 60. Chan TCY, Cheng GPM, Wang Z, et al (2015) Vector Analysis of Corneal Astigmatism after Combined Femtosecond-Assisted Phacoemulsification and Arcuate Keratotomy. *Am J Ophthalmol* 160:250-255.e2. <https://doi.org/10.1016/j.ajo.2015.05.004>
 61. Kaufmann C, Peter J, Ooi K, et al (2005) Limbal relaxing incisions versus on-axis incisions to reduce corneal astigmatism at the time of cataract surgery. *J Cataract Refract Surg* 31:2261–2265. <https://doi.org/10.1016/j.jcrs.2005.08.046>
 62. Muftuoglu O, Dao L, Cavanagh HD, et al (2010) Limbal relaxing incisions at the time of apodized diffractive multifocal intraocular lens implantation to reduce astigmatism with or without subsequent laser in situ keratomileusis. *J Cataract Refract Surg* 36:456–464. <https://doi.org/10.1016/j.jcrs.2009.10.037>
 63. Cooper BA, Holekamp NM, Bohigian G, Thompson PA (2003) Case-control study of endophthalmitis after cataract surgery comparing scleral tunnel and clear corneal wounds. *Am J Ophthalmol* 136:300–305. [https://doi.org/10.1016/S0002-9394\(03\)00202-2](https://doi.org/10.1016/S0002-9394(03)00202-2)
 64. Kankariya VP, Diakonis VF, Kymionis GD, Yoo SH (2014) Anterior gas breakthrough during Femtosecond Intrastromal Astigmatic Keratotomy (FISK). *J Refract Surg* 30:511–513. <https://doi.org/10.3928/1081597X-20140711-02>

- 1
2
3
4
5
6
7
8
9
10
11
12
13
14
15
16
17
18
19
20
21
22
23
24
25
26
65. Chang JSM (2018) Femtosecond laser-assisted astigmatic keratotomy: a review. *Eye Vis* 5:6.
<https://doi.org/10.1186/s40662-018-0099-9>
66. Vickers LA, Gupta PK (2016) Femtosecond laser-assisted keratotomy. *Curr Opin Ophthalmol* 27:277–284. <https://doi.org/10.1097/ICU.0000000000000267>
67. Wu E (2011) Femtosecond-assisted astigmatic keratotomy. *Int Ophthalmol Clin* 51:77–85.
<https://doi.org/10.1097/IIO.0b013e31820f26cd>
68. Dick HB, Schultz T, Gerste RD (2014) Lessons from a corneal perforation during femtosecond laser-assisted cataract surgery. *J Cataract Refract Surg* 40:2168–2169.
<https://doi.org/10.1016/j.jcrs.2014.10.018>

27
28
29
30
31
32
33
34

Figure Legends

Figure 1 – Flowchart diagram

35
36
37
38
39
40
41
42

Table Legends

Table 1 – Manual relaxing incision design and method characteristics

Table 2 – Femtosecond laser-assisted arcuate keratotomy design and method characteristics

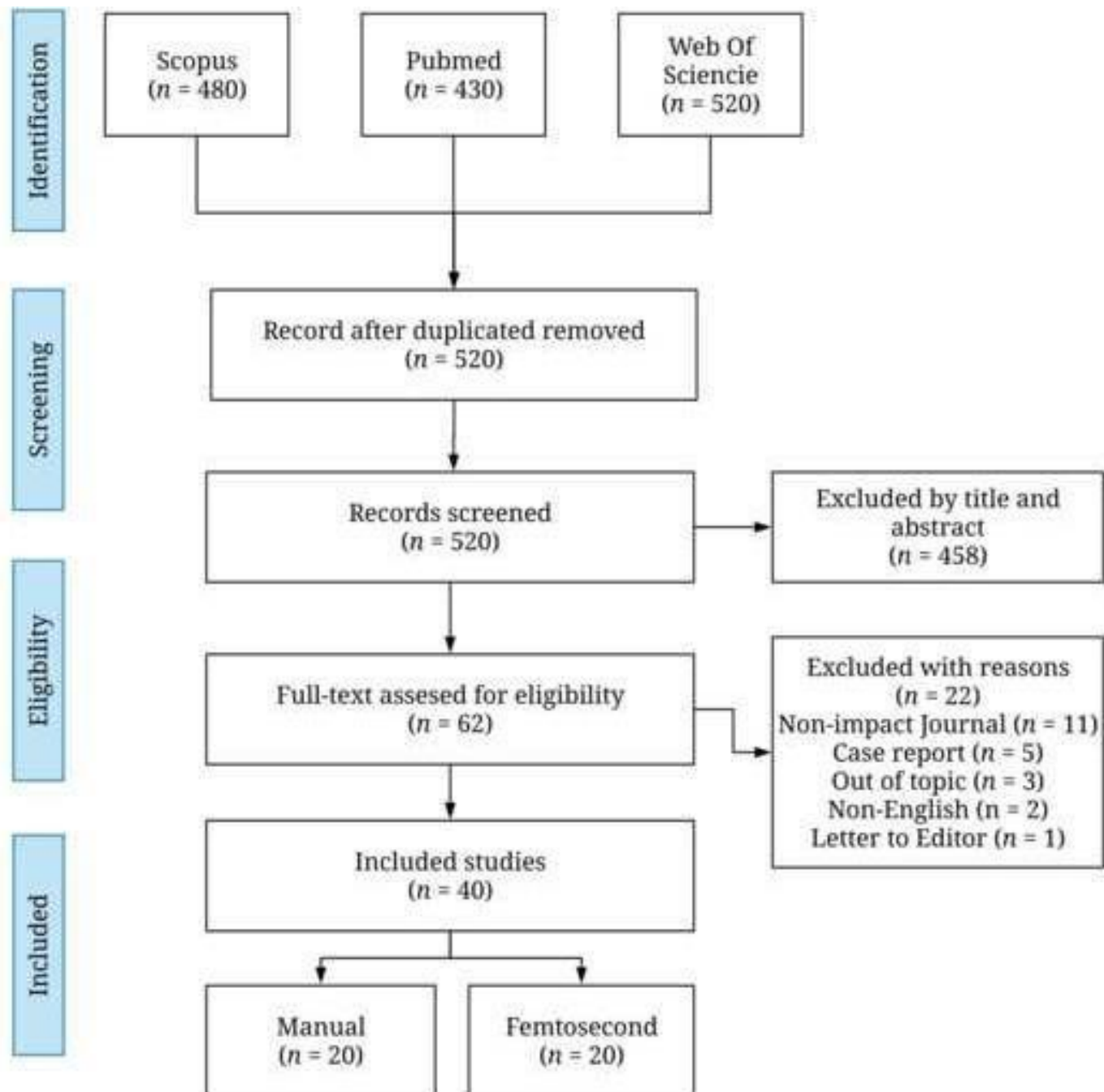
Table 3 – Manual relaxing incision resume results

Table 4 – Femtosecond laser-assisted arcuate keratotomy resume results

Table 5 – Manual relaxing incision risk of bias

Table 6 – Femtosecond laser-assisted arcuate keratotomy risk of bias

52
53
54
55
56
57
58
59
60
61
62
63
64
65



Table

Autor (date)	Design	Follow-up (month)	Patients	Eyes	Gender M/F	Mean age	Pre-operative astigmatism (D)	Incision Size (Arc length. mm or Nomogram)	Incision depth (μm)	Incision Type	Incision number	Phacoemulsification incision	Incision overlaps
Fouda et al. ¹ 2010	CS	6	15	20	6/9	68.10 \pm 12.0	≥ 1.25	Modified Gills	80%	LRI	2	Temporal	No
Ouchi et al. ² 2010	CS	6	77	96	32/45	70.8 \pm 7.9	≥ 0.75	Fukuyama	80-90%	LRI	2	Temporal/Superior and oblique	No
Ganekal et al. ³ 2011	CS	6	200	200	115/85	58 \pm 11.5	≥ 1.00	Nichamin	600	LRI	1-2	Temporal	NR
Miyata et al. ⁴ 2011	CS	1	36	44	NR	76.5 \pm 5.9	≥ 2.0	80°	550	LRI	2	NR	NR
Freitas et al. ⁵ 2014	CS	6	16	32	8/8	71.75 \pm 8.87	≥ 0.75 & ≤ 2.50	Donnenfeld	600	LRI	1-2	Temporal	NR
Lim et al. ⁶ 2014	CS	36	20	20	8/12	79 (IQR 73. 83)	> 1.2	Modified Gills	600	LRI	1-2	Temporal / On axis	NR
Maedel et al. ⁷ 2014	CS	3	21	21	NR	70.1 \pm 11.8	≥ 1.00 & ≤ 2.50	2.85 mm	Penetrating	OCCI	2	On axis	Yes
Nemeth et al. ⁸ 2014	CS	2	81	81	NR	71.02 \pm 13.26	≥ 1.00	3.00 mm	Penetrating	OCCI	2	On axis	Yes
Razmjoo et al. ⁹ 2014	CS	3	50	50	23/27	65.9 \pm 10.17	> 1.50	3.2 mm	Penetrating	CCI / OCCI	1-2	On axis	Yes
Roberts et al. ¹⁰ 2014	CS	6	13	20	7/6	68.8 \pm 13.4	≥ 1.75 & ≤ 5.25	Lindstrom	95%	AK	2	Temporal	No
Titiyal et al. ¹¹ 2014	CS	3	17	17	NR	62.23 \pm 3.29	≥ 1.25 & ≤ 3.00	30°	100% TPP	AK	2	Temporal	No
Chiam. ¹² 2015	CS	6	84	84	27/57	73.53 \pm 9.4	≥ 1.50 & ≤ 2.50	3.2/ 3.5 mm	Penetrating	OCCI	2	On-axis	Yes
Leon et al. ¹³ 2015	CS	6	48	50	22/28	70.9 \pm 7.3	> 1.00 & 2.00	Nichamin	600 or 85%	LRI	2	On-axis	No
Monaco et al. ¹⁴ 2015	CS	36	48	64	21/27	70.6 \pm 8.4	> 0.50	Donnenfeld	600	LRI	1-2	Temporal	No
Eliwa et al. ¹⁵ 2016	CS	1	17	23	8/9	61.07 \pm 13.14	> 1.00 & 3.00	Donnenfeld	600	LRI	1	On-axis	No
Lam et al. ¹⁶ 2016	CS	3	29	29	11/18	67.7 \pm 6.9	≤ 3.00	Nichamin	600	LRI	Nomogram	Temporal	NR
Mohammad-Rabei et al. ¹⁷ 2016	CS	6	17	17	9/5	63.1 \pm 12.4	≥ 1.25	Modified Gills	600 or Penetrating	LRI	1-2	Temporal/ On axis	Both
Roberts et al. ¹⁸ 2018	CS	1	51	51	22/29	72.5 \pm 10.5	> 0.90	Donnenfeld	600	LRI	2	On axis /Off axis	Both
Ren et al. ¹⁹ 2019	CS	3	68	68	31/37	66.16 \pm 11.87	≥ 0.75	2 / 3 mm	Penetrating	OCCI	2	On axis	Yes
Stanojic et al. ²⁰ 2020	CS	1	38	38	17/21	70.3 \pm 14.7	≥ 2.00	Donnenfeld	600	LRI	2	On axis	Yes

M: Male; F: Female; D: Diopter NR: Not reported; CS: Case Series; IQR: Interquartile Range; TPP: Thickness Paracentral Pachymetry; AK: Arcuate Keratotomy; LRI: limbal relaxing incision; OCCI: opposite clear corneal incision; WTR: With the rule; ATR: Against the rule.

Table

Author (date)	Design	Follow-up (months)	Patients	Eyes	Gender M/F	Mean age	Pre-operative corneal astigmatism (D)	Laser Platform	Incision Nomogram	Incision depth	Incision type	Incision number	Diameter	Phacoemulsification incision
Rückl et al. ¹ 2013	CS	6	16	16	8/8	65 ± 12	> 1.0 & <3.0	IntraLase iFS	90° arc length	IE	AK	2	7.5	NR
Yoo et al. ² 2015	CS	5	23	23	NR	53.6 ± 16.6	> 1.0 & <3.0	IntraLase iFS	30% Donnenfeld	85% PT	AK	2	9	On-axis
Day et al. ³ 2016	CS	1	133	196	NR	62.1 ± 9.0	> 0.70	Catalys Laser	Personalized	60% IE	AK	2	8	Temporal
Day et al. ⁴ 2016a	CS	1	213	319	NR	61.3 ± 10.1	> 0.75 & <2.50	Catalys Laser	Personalized	60% IE	AK	2	8	Temporal
Day et al. ⁵ 2016b	CS	6	NR	87	NR	60.4 ± 11.6	NR	Catalys Laser	Personalized	60% IE	AK	2	8	Temporal
Baharozian et al. ⁶ 2017	CS	1-2	116	161	NR	67 ± 10	≥0.25 & ≤2.00	Catalys Laser	Donnenfeld	80% PT	AK	1 or 2	9	Temporal
Blehm et al. ⁷ 2017	CS	2	18	28	6/12	68.8 ± 6.1	≥1.0 & <2.4	LenSx	Woodcock	90% PT	AK	2	8	NR
Löffler et al. ⁸ 2017	CS	3	23	27	NR	65 ± 8	≥ 0.75	LenSx	Wang	80% PT	AK	1 or 2	9	NR
Byun et al. ⁹ 2018	CS	6	89	89	17/72	63.8 ± 10.2	NR	Catalys Laser	Julian Stevens	60% IE	AK	2	8	NR
Roberts et al. ¹⁰ 2018	CS	1	53	53	31/22	69.7 ± 12.0	>0.90	LenSx	Day	NR	AK	NR	NR	On axis
Lee et al. ¹¹ 2019	CS	1	NR	14	NR	NR	>0.75	Catalys Laser	Julian Stevens	NR	AK	NR	NR	NR
Visco et al. ¹² 2019	CS	3	143	189	56/87	68.3 ± 8.1	≥0.50 & ≤2.0	LenSx Laser	Nichamin-Woodcock	90% PT	AK	2	8.6	Temporal
Chen et al. ¹³ 2020	CS	3	138	138	58/60	59.5 ± 13.3	≥0.75 & ≤2.50	LenSx	Personalized	100% PT	OCCI	1 or 2	NR	NR
Ganesh et al. ¹⁴ 2020	CS	6	25	25	NR	64.5 ± 10.1	≥0.75 & ≤2.00	Catalys Laser	20% Donnenfeld	PT	AK	2	8	Temporal
			25	25	NR	62 ± 9.2			Intrastromal AK	60% IE	AK	2	8	Temporal
Lim et al. ¹⁵ 2020	CS	3	125	154	61/93	71.4 ± 9.3	≥0.20	Catalys Laser	Single, non-paired LRIs	60% IE	AK	1	9	Temporal
Rani et al. ¹⁶ 2020	CS	3	70	80	42/28	63 ± 9.1	≥0.40 & ≤1.50	Catalys- I Precision	Donnenfeld	80% PT	AK	Nomogram	8	Temporal
Wortz et al. ¹⁷ 2020	CS	1	124	124	53/71	66.8 ± 8.0	<1.0D	Catalys- I Precision	Wörtz-Gupta™	80% PT	AK	1 or 2	9	Temporal
Moon et al. ¹⁸ 2021	CS	3	79	79	35/44	66.9 ± 10.7	>0.50 & ≤3.00	Catalys- I Precision	Julian Stevens	60% IE	AK	2	8	NR
Schwarzenbacher et al. ¹⁹ 2021	CS	24	43	43	NR	73 ± 11	≥1.00 & ≤3.00	LDV Z8	Castrop Femto	80% PT	AK	2	8.5	Temporal
Wendelstein et al. ²⁰ 2021	CS	12	27	35	14/13	69	≥0.50 & ≤2.50	Technolas Victus	Castrop Femto	80% PT	AK	2	8.5	Temporal

M: Male; F: Female; D: Diopter NR: Not reported; CS: Case Series; IE: Intraestromal; PT: Penetrating; AK: Arcuate Keratotomy; LRI: Limbal relaxing incision; WTR: With the rule; ATR: Against the rule; OBL: Oblique

Table

Author (date)	UDVA		CDVA		Mean keratometric astigmatism (D)		Mean Refractive Cylinder (D)		TIA	SIA
	Preoperative	Postoperative	Preoperative	Postoperative	Preoperative	Postoperative	Preoperative	Postoperative		
Fouda et al. ¹ 2010	1.06 ± 0.53	0.49	0.49 ± 0.47	0.07	2.03 ± 0.49	1.34 ± 0.60	-1.72 ± 0.95	-0.98 ± 0.58	2.03 ± 0.49	1.33 ± 0.75
Ouchi et al. ² 2010	0.46 ± 0.72	0.03 ± 0.47	0.29 ± 0.32	-0.05 ± 0.52	1.79 ± 1.01	NR	NR	0.56 ± 0.87	1.79 ± 1.01	1.44 ± 0.79
Ganekal et al. ³ 2011	NR	≥ 6/9 (76.5 %)	NR	≥ 6/9 (99.5 %)	1.58 ± 0.55	0.45 ± 0.25	NR	NR	1.58 ± 0.55	NR
Miyata et al. ⁴ 2011	0.31 ± 0.14	0.006 ± 0.14	-0.10 ± 0.07	-0.15 ± 0.05	2.03 ± 0.92	1.33 ± 0.69	-2.61 ± 0.78	-0.74 ± 0.60	2.03 ± 0.92	NR
	0.34 ± 0.14	0.05 ± 0.15	-0.10 ± 0.07	-0.12 ± 0.08	2.36 ± 0.77	0.93 ± 0.70	-2.67 ± 0.80	-0.76 ± 0.54	2.36 ± 0.77	NR
Freitas et al. ⁵ 2014	NR	0.15	0.44	0.05	1.32 ± 0.47	NR	NR	-0.74 ± 0.26	1.58	1.08
Lim et al. ⁶ 2014	NR	NR	NR	NR	2.2 (IQR 2.0 to 3.0)	1.0 (IQR 0.8 to 1.3)	NR	NR	2.2 (IQR 2.0 to 3.0)	1.7 (IQR 1.1 to 2.1)
	NR	NR	NR	NR	1.9 (IQR 1.6 to 2.4)	1.0 (IQR 0.4 to 1.4)	NR	NR	1.9 (IQR 1.6 to 2.4)	1.9 (IQR 1.6 to 2.8)
Maedel et al. ⁷ 2014	NR	0.29 ± 0.30	NR	0.08 ± 0.16	1.67 ± 0.30	0.96 ± 0.70	NR	1.02 ± 0.54	1.67 ± 0.30	NR
Nemeth et al. ⁸ 2014	NR	NR	NR	NR	1.06 ± 0.34	0.86 ± 0.68	NR	NR	1.06 ± 0.34	0.99 ± 0.57
Razmjoo et al. ⁹ 2014	NR	NR	NR	NR	2.58 ± 1.03	2.15 ± 0.82	NR	NR	2.58 ± 1.03	1.01 ± 1.02
	NR	NR	NR	NR	2.70 ± 0.94	1.63 ± 1.21	NR	NR	2.70 ± 0.94	1.59 ± 0.70
Roberts et al. ¹⁰ 2014	NR	NR	NR	NR	NR	NR	-2.41 ± 0.76	-1.33 ± 0.76	NR	NR
Titiyal et al. ¹¹ 2014	1.15 ± 0.51	NR	0.23 ± 0.66	NR	2.18 ± 0.59	0.57 ± 0.41	1.95 ± 0.47	0.99 ± 0.54	2.18 ± 0.59	NR
Chiam ¹² 2015	NR	0.2 R (0.0 to 0.3)	0.3 R (0.2 to 0.5)	0.1 R (0.1 to 0.2)	1.9 R (1.6 to 2.3)	NR	NR	0.5 ± 0.5	1.9 R (1.6 to 2.3)	1.6 R (1.0 to 2.1)
	NR	0.3 R (0.1 to 0.5)	0.3 R (0.2 to 0.6)	0 R (0.1 to 0.2)	1.9 R (1.5 to 2.4)	NR	NR	1.3 ± 0.5	1.9 R (1.5 to 2.4)	0.8 R (0.6 to 1.2)
	NR	0.2 R (0.0 to 0.4)	0.4 R (0.2 to 0.5)	0 R (0.1 to 0.2)	1.9 R (1.5 to 2.4)	NR	NR	0.6 ± 0.6	1.9 R (1.5 to 2.4)	1.5 R (1.1-1.8)
Leon et al. ¹³ 2015	0.79 ± 0.31	0.22 ± 0.12	0.39 ± 0.13	0.05 ± 0.04	2.16 ± 0.40	0.84 ± 0.46	1.91 ± 0.63	1.1 ± 0.38	2.16 ± 0.40	NR
Monaco et al. ¹⁴ 2015	0.70 ± 0.19	0.12 ± 0.01	0.51 ± 0.24	0.02 ± 0.00	2.22 ± 2.61	1.33 ± 2.03	NR	NR	2.22 ± 2.61	NR
Eliwa et al. ¹⁵ 2016	NR	NR	NR	NR	1.60 ± 0.50	0.87 ± 0.49	NR	NR	1.33 ± 0.20	1.29 ± 0.71
Lam et al. ¹⁶ 2016	0.79 ± 0.26	0.336 ± 0.153	NR	NR	-1.19 ± 0.45	-0.81 ± 0.50	-1.58 ± 0.28	-1.00 ± 0.60	1.19 ± 0.45	NR
Mohammad-Rabei et al. ¹⁷ 2016	0.71 ± 0.33	0.18 ± 0.15	0.49 ± 0.29	NR	1.89 ± 0.51	0.78 ± 0.63	-1.30 ± 1.25	NR	1.89 ± 0.51	1.78 ± 0.65
	0.75 ± 0.42	0.12 ± 0.13	0.51 ± 0.38	NR	1.78 ± 0.51	0.52 ± 0.33	-1.06 ± 1.37	NR	1.78 ± 0.51	1.65 ± 0.63
Roberts et al. ¹⁸ 2018	NR	>20/25 (37%)	0.45 ± 0.38	>20/25 (61%)	1.50 ± 0.46	1.17 ± 0.69	1.42 ± 0.79	1.18 ± 0.90	1.50 ± 0.46	1.02 ± 0.41
Ren et al. ¹⁹ 2019	0.42 ± 0.93	0.18 ± 0.20	NR	0.07 ± 0.08	1.09 ± 0.52	0.52 ± 0.48	NR	NR	1.09 ± 0.52	1.07 ± 0.51
	0.78 ± 0.71	0.11 ± 0.15	NR	0.04 ± 0.07	0.99 ± 0.30	0.69 ± 0.42	NR	NR	0.99 ± 0.30	0.61 ± 0.35
Stanojic et al. ²⁰ 2020	0.82 ± 0.55	0.27 ± 0.15	0.41 ± 0.38	0.06 ± 0.12	2.87 ± 0.78	2.16 ± 0.98	2.96 ± 1.39	1.91 ± 1.07	2.87 ± 0.78	2.35 ± 1.79

NR: Not reported; D: Diopter; IQR: Interquartile Range; R: Range; UDVA: Uncorrected distance visual acuity; CDVA: Corrected distance visual acuity; TIA: Target induced astigmatism; SIA: Surgically induced astigmatism

Table

Author (date)	UDVA		CDVA		Mean keratometric astigmatism (D)		Mean Refractive Cylinder (D)		TIA	SIA	CI	IS
	Pre	Post	Pre	Post	Pre	Post	Pre	Post				
Rückl et al. ¹ 2013	0.45 ± 0.27	0.26 ± 0.33	0.09 ± 0.15	0.12 ± 0.18	1.50 ± 0.47	0.63 ± 0.34	1.41 ± 0.66	0.33 ± 0.42	1.50 ± 0.47	1.59 ± 0.70	1.00 ± 0.44	NR
Yoo et al. ² 2015	0.52 ± 0.06	0.17 ± 0.03	0.34 ± 0.06	0.05 ± 0.02	1.31 ± 0.13	0.874 ± 0.135	1.71 ± 0.15	0.78 ± 0.10	1.31 ± 0.13	NR	0.81 ± 0.33	NR
Day et al. ³ 2016	NR	NR	NR	NR	NR	NR	1.21 ± 0.42	0.74 ± 0.38	1.21 ± 0.42	0.74 ± 0.40	0.63 ± 0.32	0.63 ± 0.30
Day et al. ⁴ 2016a	NR	NR	NR	NR	NR	NR	1.24 ± 0.44	0.79 ± 0.41	1.24 ± 0.44	0.71 ± 0.43	0.59 ± 0.31	0.65 ± 0.29
Day et al. ⁵ 2016b	NR	NR	NR	NR	1.23 ± 0.49	NR	NR	NR	1.23 ± 0.49	0.69 ± 0.50	NR	NR
Baharozian et al. ⁶ 2017	NR	NR	NR	NR	0.86 ± 0.32	0.63 ± 0.42	NR	NR	0.86 ± 0.32	NR	0.53 WTR, 1.01 ATR, and 0.95 OBL	NR
Blehm et al. ⁷ 2017	NR	79% ↑ > one line	NR	NR	1.42 ± 0.54	NR	1.35 ± 0.30	71% ≤ 0.50	1.42 ± 0.54	NR	NR	NR
Löffler et al. ⁸ 2017	NR	NR	NR	NR	0.97 ± 0.30	0.63 ± 0.34	NR	NR	0.97 ± 0.30	0.71 ± 0.37	NR	NR
Byun et al. ⁹ 2018	NR	NR	NR	NR	1.16 ± 0.46	0.63 ± 0.35	1.54 ± 1.05	0.43 ± 0.37	1.16 ± 0.46	0.91 ± 0.50	0.87 ± 0.50	0.57 ± 0.34
Roberts et al. ¹⁰ 2018	NR	>20/25 (40%)	0.69 ± 0.52	>20/25 (67%)	1.38 ± 0.40	0.89 ± 0.54	-1.34 ± 0.99	0.90 ± 0.50	1.38 ± 0.40	1.25 ± 0.77	0.73 ± 0.49	0.65 ± 0.4
Lee et al. ¹¹ 2019	NR	0.10 ± 0.09	NR	NR	1.10 ± 0.54	0.59 ± 0.18	1.51 ± 0.97	0.63 ± 0.43	1.10 ± 0.54	NR	NR	NR
Visco et al. ¹² 2019	NR	0.09 ± 0.16	NR	0.02 ± 0.05	0.92 ± 0.34	0.14 ± 0.23	NR	NR	0.92 ± 0.34	0.88 ± 0.35	0.94	NR
Chen et al. ¹³ 2020	NR	0.16 ± 0.13	0.62 ± 0.38	NR	1.31 ± 0.41	0.69 ± 0.34	NR	54% < 0.50	1.31 ± 0.41	1.02 ± 0.54	0.72 ± 0.36	0.48 ± 0.20
Ganesh et al. ¹⁴ 2020	NR	0.12 ± 0.08	NR	0.008 ± 0.05	1.07 ± 0.39	0.65 ± 0.28	NR	0.29 ± 0.35	1.16 ± 0.63	1.23 ± 0.86	0.95	0.71
	NR	0.18 ± 0.09	NR	0.02 ± 0.06	1.23 ± 0.88	0.90 ± 0.74	NR	0.56 ± 0.19	1.50 ± 0.93	1.08 ± 0.85	0.55	0.59
Lim et al. ¹⁵ 2020	NR	NR	NR	NR	0.87 ± 0.42	0.87 ± 0.51	NR	0.61 ± 0.46	0.87 ± 0.42	0.80 ± 0.52	0.79 ± 0.72	0.93 ± 0.65
Rani et al. ¹⁶ 2020	NR	NR	NR	NR	0.85 ± 0.27	0.47 ± 0.27	NR	NR	0.85 ± 0.27	0.38 ± 0.32	NR	NR
Wortz et al. ¹⁷ 2020	NR	20/25 86.3%	NR	NR	0.611 ± 0.187	-0.256 ± 0.284	NR	NR	0.61 ± 0.19	NR	NR	NR
Moon et al. ¹⁸ 2021	NR	NR	NR	NR	1.23 ± 0.52	0.80 ± 0.45	NR	NR	1.21 ± 0.52	0.76 ± 0.53	0.62 ± 0.34	NR
Schwarzenbacher et al. ¹⁹ 2021	NR	NR	0.26 ± 0.17	0.03 ± 0.12	1.62 ± 0.49	0.66 ± 0.38	NR	NR	1.24 ± 0.46	0.95 ± 0.48	NR	NR
Wendelstein et al. ²⁰ 2021	0.84 ± 0.50	0.13 ± 0.30	0.30 ± 0.14	-0.04 ± 0.10	1.43 ± 0.34	0.55 ± 0.35	NR	0.27 ± 0.23	1.43 ± 0.34	1.39 ± 0.42	0.98 ± 0.20	0.20 ± 0.18

NR: Not reported; D: Diopter; UDVA: Uncorrected distance visual acuity; CDVA: Corrected distance visual acuity; TIA: Target induced astigmatism; SIA: Surgically induced astigmatism; CI: Correction index; IS: Index of success; WTR: with the rule; ATR: Against the rule; OBL: Oblique

Author and Date	Q1	Q2	Q3	Q4	Q5	Q6	Q7
Fouda et al. ¹ 2010	Yes	Yes	Yes	Yes	Yes	Yes	Yes
Ouchi et al. ² 2010	No	No	No	Yes	No	Yes	No
Ganekal et al. ³ 2011	Yes	Yes	Yes	Yes	No	Yes	No
Miyata et al. ⁴ 2011	Yes	Yes	Yes	Yes	No	No	No
Freitas et al. ⁵ 2014	Yes	Yes	Yes	Yes	Yes	Yes	No
Lim et al. ⁶ 2014	Yes	Yes	Yes	No	No	Yes	No
Maedel et al. ⁷ 2014	Yes	Yes	No	No	No	No	No
Nemeth et al. ⁸ 2014	Yes	Yes	Yes	No	Yes	No	No
Razmjoo et al. ⁹ 2014	Yes	Yes	Yes	Yes	No	No	No
Roberts et al. ¹⁰ 2014	Yes	Yes	Yes	No	Yes	Yes	No
Titiyal et al. ¹¹ 2014	Yes	Yes	Yes	Yes	No	No	No
Chiam ¹² 2015	Yes	Yes	Yes	Yes	Yes	Yes	No
Monaco et al. ¹³ 2015	Yes	Yes	Yes	Yes	No	Yes	No
Leon et al. ¹⁴ 2015	Yes	Yes	Yes	Yes	Yes	Yes	No
Eliwa et al. ¹⁶ 2016	Yes	Yes	Yes	Yes	Yes	No	No
Lam et al. ¹⁵ 2016	Yes	Yes	Yes	No	No	No	No
Mohammad-Rabei et al. ¹⁷ 2016	Yes	No	No	No	Yes	Yes	No
Roberts et al. ¹⁸ 2018	Yes	Yes	No	Yes	No	No	Yes
Ren et al. ¹⁹ 2019	Yes	Yes	Yes	Yes	No	Yes	Yes
Stanojic et al. ²⁰ 2020	Yes	Yes	Yes	No	No	No	Yes

NA: Not applied; Q= Question; (Q1): Is the study oriented to a clear question?; (Q2): Were all the patients results taken into account?; (Q3): Was the follow-up complete?; (Q4): Were the same conditions used in surgical treatment?; (Q5): Was the intervention clearly described?; (Q6): Was the duration of follow-up adequate?; (Q7): Were the results described correctly?

Author and Date	Q1	Q2	Q3	Q4	Q5	Q6	Q7
Rückl et al. ¹ 2013	Yes	No	Yes	Yes	Yes	Yes	Yes
Yoo et al. ² 2015	Yes	Yes	Yes	Yes	Yes	No	No
Day et al. ³ 2016	Yes	Yes	Yes	Yes	Yes	No	Yes
Day et al. ⁴ 2016a	Yes	Yes	Yes	Yes	Yes	No	Yes
Day et al. ⁵ 2016b	Yes	Yes	Yes	Yes	No	Yes	No
Baharozian et al. ⁶ 2017	Yes	Yes	No	Yes	Yes	No	No
Blehm et al. ⁷ 2017	Yes	Yes	Yes	Yes	No	No	No
Löffler et al. ⁸ 2017	Yes	Yes	Yes	Yes	Yes	No	No
Byun et al. ⁹ 2018	Yes	Yes	Yes	Yes	No	Yes	No
Roberts et al. ¹⁰ 2018	Yes	Yes	No	Yes	No	No	Yes
Lee et al. ¹¹ 2019	No	No	Yes	Yes	No	No	No
Visco et al. ¹² 2019	Yes	Yes	No	Yes	No	No	Yes
Chen et al. ¹³ 2020	Yes	Yes	No	Yes	No	No	Yes
Ganesh et al. ¹⁴ 2020	Yes	Yes	Yes	Yes	Yes	Yes	Yes
Lim et al. ¹⁵ 2020	Yes	Yes	Yes	Yes	Yes	Yes	Yes
Rani et al. ¹⁶ 2020	Yes	Yes	Yes	Yes	Yes	No	No
Wortz et al. ¹⁷ 2020	Yes	Yes	Yes	Yes	Yes	No	No
Moon et al. ¹⁸ 2021	Yes	Yes	Yes	Yes	Yes	No	Yes
Schwarzenbacher et al. ¹⁹ 2021	Yes	Yes	No	Yes	Yes	Yes	No
Wendelstein et al. ²⁰ 2021	Yes	Yes	No	Yes	Yes	Yes	Yes

NA: Not applied; Q= Question; (Q1): Is the study oriented to a clear question; (Q2): Were all the patients results taken into account; (Q3): Was the follow-up complete; (Q4): Were the same conditions used in surgical treatment; (Q5): Was the intervention clearly described; (Q6): Was the duration of follow-up adequate; (Q7): Were the results described correctly?