











ORIGINAL ARTICLE

Comprehensive management of paranasal sinus fungus balls: A Young-IFOS consensus statement

Alberto Maria Saibene MD, MA^{1,2}  | Fabiana Allevi MD, PhD^{1,3}  |
 Christian Calvo-Henriquez MD^{1,4}  | Nicolas Dauby MD, PhD⁵  |
 Daniele Dondossola MD⁶ | Rémi Hervochon MD, MSc^{1,7}  | Jérôme R. Lechien MD,
 PhD, MS^{1,8} | David Lobo-Duro MD, PhD^{1,9}  | Luca Giovanni Locatello MD^{1,10}  |
 Antonino Maniaci MD^{1,11} | Giuditta Mannelli MD, PhD^{1,12} | Miguel Mayo-Yáñez MD,
 MSc^{1,13,14}  | Juan Maza-Solano MD, PhD^{1,15} | Thomas Radulesco MD, PhD, MS^{1,16} |
 Neil Tan BSc, MD, PhD, FRCS, MBBS^{1,17,18} | Camilla Tincati MD¹⁹ |
 Manuel Tucciarone MD^{1,20} | Luigi Angelo Vaira MD^{1,21}  |
 Leigh Sowerby MD, MHM, FRCSC^{1,22} 

¹Young Otolaryngologists–International Federation of Otorhinolaryngological Societies, Paris, France

²Otolaryngology Unit, ASST Santi Paolo E Carlo, Department of Health Sciences, Università Degli Studi Di Milano, Milan, Italy

³Maxillofacial Surgery Unit, ASST Santi Paolo E. Carlo, Department of Health Sciences, Università Degli Studi Di Milano, Milan, Italy

⁴Otolaryngology, Rhinology and Sleep Apnea Unit, Hospital Complex of Santiago de Compostela, Santiago de Compostela, Spain

⁵Department of Infectious Diseases, CHU Saint-Pierre, Université Libre de Bruxelles, School of Public Health, Université Libre de Bruxelles & Institute for Medical Immunology, Brussels, Belgium

⁶Department of General and Liver Transplant Surgery Unit, Fondazione IRCCS Ca' Granda, Ospedale Maggiore Policlinico, Milan, Italy

⁷ENT Department, Pitié Salpêtrière Hospital, Paris, France

⁸Department of Head and Neck Surgery, Foch Hospital, Paris Saclay University, Paris, France

⁹Rhinology, Endoscopic Sinus & Skull Base Surgery, Hospital Universitario Marqués de Valdecilla, Santander, Spain

¹⁰Department of Otorhinolaryngology, Sant'Antonio Abate Hospital, Azienda Sanitaria Universitaria Friuli Centrale, Tolmezzo, Italy

¹¹Department of Medical, Surgical Sciences and Advanced Technologies G.F. Ingrassia, University of Catania, Catania, Italy

¹²Department of Experimental and Clinical Medicine, University of Florence, Florence, Italy

¹³Otorhinolaryngology-Head and Neck Surgery Department, Complejo Hospitalario Universitario A Coruña, A Coruña, Galicia, Spain

¹⁴Clinical Research in Medicine, International Center for Doctorate and Advanced Studies, Universidade de Santiago de Compostela, Santiago de Compostela, Galicia, Spain

¹⁵Rhinology & Skull Base Surgery, ENT Department, University Hospital Virgen Macarena of Sevilla, Sevilla, Spain

¹⁶Service ORL et Chirurgie Cervico-Faciale du Pr Michel, Hôpital de la Conception, Marseille, France

¹⁷Department of Otolaryngology, Royal Cornwall Hospital, Truro, UK

¹⁸College of Medicine and Health, University of Exeter Medical School, Exeter, UK

¹⁹Infectious Diseases Clinic, Santi Paolo e Carlo Hospital, Department of Health Sciences, University of Milan, Milan, Italy

²⁰Department of Otorhinolaryngology and Head and Neck Surgery, Jerez University Hospital, Jerez de la Frontera, Spain

²¹Department of Medical, Surgical and Experimental Sciences, Maxillofacial Surgery Operative Unit, University of Sassari, Sassari, Italy

²²Department of Otolaryngology, Western University, London, ON, Canada

Alberto Maria Saibene and Fabiana Allevi contributed equally to this article.

This is an open access article under the terms of the [Creative Commons Attribution-NonCommercial License](https://creativecommons.org/licenses/by-nc/4.0/), which permits use, distribution and reproduction in any medium, provided the original work is properly cited and is not used for commercial purposes.

© 2022 The Authors. *International Forum of Allergy & Rhinology* published by Wiley Periodicals LLC on behalf of American Academy of Otolaryngic Allergy and American Rhinologic Society.

Correspondence to: Alberto Maria Saibene, Otolaryngology Unit, ASST Santi Paolo e Carlo, Via Antonio di Rudini, 8, Milan 20142, Italy.
 Email: alberto.saibene@unimi.it

Potential conflict of interest: None provided.

Abstract

Background: Paranasal sinus fungus balls (PSFB) are a common form of surgically treatable, noninvasive mycosis. To date, no guidelines have standardized PSFB treatment or management of difficult cases (eg, immunocompromised or fragile patients). The clinical consensus statement presented herein aims to provide a comprehensive management guide to PSFB based on current evidence.

Methods: A multidisciplinary, international panel of 19 specialists judged statements in 3 rounds of a modified Delphi method survey. Statements encompassed the following PSFB management issues: definition, diagnostic workup; treatment indications and modalities; and follow-up. Otolaryngologists, maxillofacial surgeons, infectious disease specialists, and transplant physicians were considered the target audience.

Results: Among the 23 statements, 7 reached strong consensus and 16 reached consensus. Consensus was reached on the definition, diagnosis, and treatment modalities for PSFB. Postoperative follow-up modalities and scenarios with bacterial superinfection were the most debated issues.

Conclusion: Until further data are available, these points provide a framework for the management of PSFB. Moreover, PSFB should be considered a noninvasive mycosis that is not necessarily symptomatic or related to odontogenic conditions. Although diagnosis may be incidental, endoscopy and single imaging (computed tomography or magnetic resonance imaging, with distinctive features) are required for diagnosis, whereas contrast medium would allow for differential diagnosis. Although treatment of PSFB should be considered mandatory before sinus augmentation and is recommended for symptomatic patients, immunosuppressed patients, or patients with planned immunosuppression, watchful waiting could be considered for asymptomatic patients with chronic rhinosinusitis who are provided with appropriate advice and assessment.

KEYWORDS

antibiotics, computed tomography, endoscopy, guideline, maxillary sinus, mycosis

1 | INTRODUCTION

Paranasal sinus fungus balls (PSFB) are generally considered a form of noninvasive mycosis¹ mostly affecting the maxillary sinus, with less common extramaxillary or multiple presentations.² PSFB incidence appears to have increased in the last 15 years, with up to 8.3% of affected patients undergoing endoscopic sinus surgery (ESS).³

Most likely due to the generally favorable prognosis and consistently high rate of resolution after ESS, which should be regarded as the sole first-line treatment option, PSFB has not been addressed by specific management guidelines to date and is only marginally considered a causative factor in secondary rhinosinusitis.⁴

The aim of this clinical consensus statement (CCS) is to offer, through a modified Delphi process, specific management guidelines for PSFB, based on the best evidence currently available, covering all disease management issues, and offering a reference for the most common difficult clinical scenarios.

2 | METHODS

The development of this CCS followed the modified Delphi protocol proposed by Rosenfeld et al.⁵ No specific approval by an internal review board was required due to the nature of the study.

2.1 | Panelists and scope of consensus statement

The panel was composed of 19 collaborators from 6 European and North American countries. The development group consisted of a chair (A.M.S.), assistant chair (L.S.), and methodologist (F.A.). Rhinologists were recruited from the rhinologist section of the Young Otolaryngologist–International Federation of Otorhinolaryngological Societies (YO-IFOS) research group, whereas non-otolaryngologic authors were selected according to their specialty training, in the context of other ongoing research collaborations with the group. The YO-IFOS research group is an invitation-only group, whose members are selected by the elected scientific committee of the YO-IFOS among worldwide board-certified otolaryngologists <45 years of age and on the basis of the extent and impact of their scientific achievements. The group is further subdivided according to members' subspecialties. As is the case for this CCS, members are free to propose new projects and participate in proposals according to their areas of expertise (although 1 completed proposal and 2 participations every 24 months are required to retain membership). The panel for this CCS was ultimately composed of 14 rhinologists, 1 epidemiologist, 1 infectious disease specialist, 1 transplant specialist, and 2 maxillofacial surgeons. No conflicts of interest emerged among the authors. The focus of the CCS was to offer specific guidance for the management of PSFB.

2.2 | Literature review

A systematic review of the literature that was in compliance with the Preferred Reporting Items for Systemic Reviews and Meta-Analysis (PRISMA) was conducted for PSFB management in the MEDLINE, EMBASE, Scopus, and Web of Science databases.⁶ Broad search strategies for “fungus ball” and all related terms in association with paranasal sinuses, nose, and related terms, were used on December 2, 2021 to look for studies in English, Italian, German, French, or Spanish that reported data obtained from human subjects. Supporting Information 1 reports the search strategies for all queried databases. Due to a lack of high-quality studies on the topic, the systematic review was extended from what had been originally been recommended for CCSs⁵ (ie, guidelines and systematic reviews) to include all original studies published on the topic, with the exclusion of case reports and non-original articles (such as narrative reviews).

Upon retrieval of the literature identified by the systematic review, a collection of 84 articles, representing the best evidence on the topic (ie, higher-evidence-level studies and

case series with at least 20 patients), was prepared and distributed to all authors for review over a period of 1 month. Figure 1 shows a PRISMA flowchart of the article selection process.

2.3 | Clinical statement development and modified Delphi survey

Based on the literature review and the aim of the CCS, the chair and assistant chair developed the core clinical statements for the survey, which were further discussed, expanded, and edited by the methodologist.

Statements were developed based on the literature review and the development group's perception of important clinical scenarios. A final 23-statement survey was therefore created and distributed to the authors using Google Forms (Google LLC, Mountain View, CA). Authors were instructed to complete the survey anonymously via a personalized and single-use link. Authors were asked to report their agreement with each statement according to a 9-point Likert scale from strongly disagree (1) to strongly agree (9). As defined by Rosenfeld [13], the results for each statement were defined as follows: strong consensus = mean score of ≥ 8.00 with no outliers (defined as any rating 2 or more Likert points from the mean in either direction); consensus = mean score of ≥ 7.00 with no more than 1 outlier; near consensus = mean score of ≥ 6.50 with no more than 2 outliers; no consensus = all other statements.

After the first survey round, 3 of 23 statements reached a strong consensus, 7 of 23 statements reached a consensus, 4 reached a near consensus, and 9 reached no consensus. The 13 near- or no-consensus items were rephrased based on anonymous comments from the authors for inclusivity and clarity. The second survey round included 13 statements, of which 4 reached a strong consensus, 6 reached a consensus, 1 reached a near consensus, and 2 did not reach a consensus. After a second rewording, a third 3-item round was prepared, in which all 3 items reached a consensus.

3 | RESULTS

All panelists took part in the 3 Delphi rounds, although 2 rhinologists missed 1 Delphi round each. After the 3 Delphi rounds, 7 of 23 statements reached a strong consensus, and the remaining 16 reached a consensus. The evolution of statements from the first round to their final version is reported in Supporting Information 2. Delphi process results for all statements, along with their mean score, median score, score range, and the respective number of outliers, are reported in Table 1.

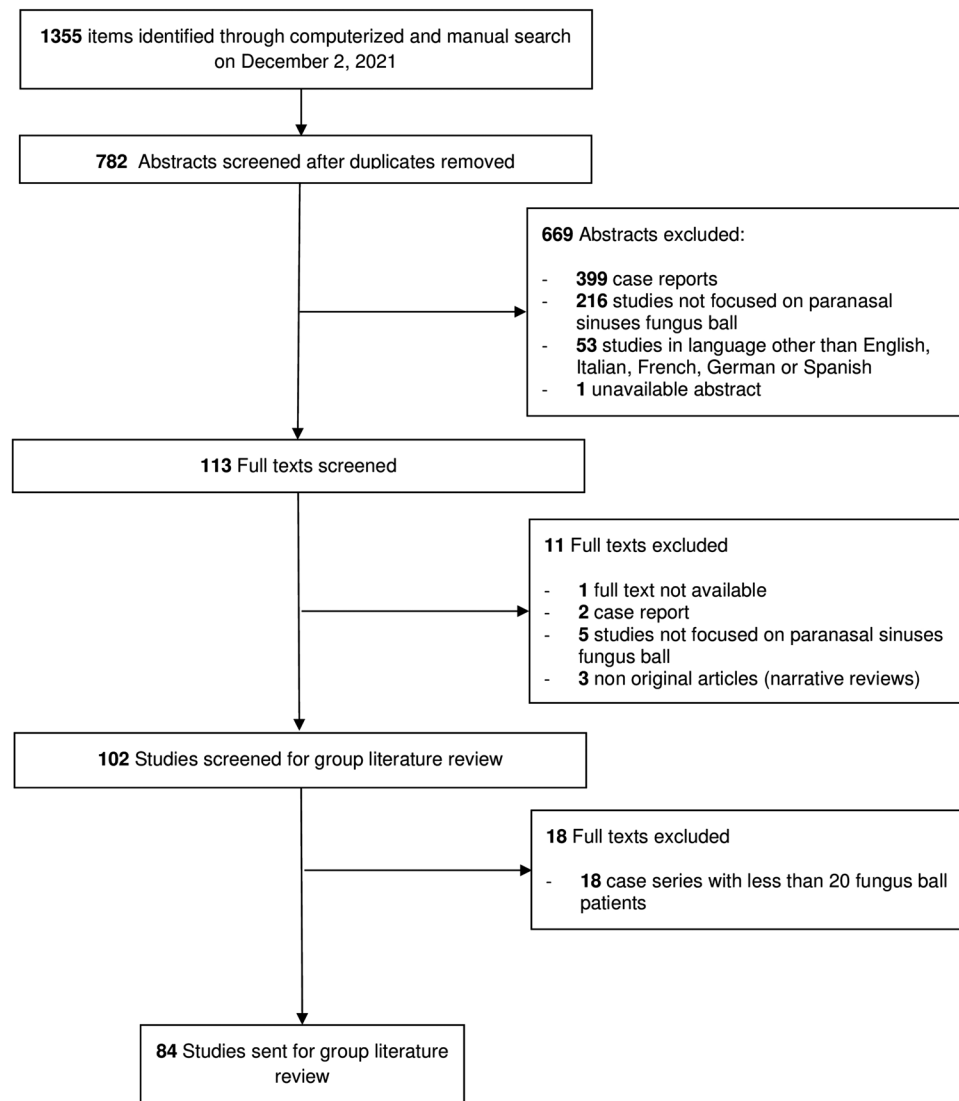


FIGURE 1 Flowchart of the article selection process according to Preferred Reporting Items for Systemic Reviews and Meta-Analysis (PRISMA).

The 2 highest scoring strong consensus items were “PSFBs may be diagnosed incidentally during other diagnostic workups without any accompanying symptoms” (mean score, 8.64; median score, 9) and “PSFB treatment is highly recommended in immunocompromised patients, especially in cases of secondary chronic rhinosinusitis (CRS)” (mean score, 8.58; median score, 9). Six of 23 items recorded a median score of 9.

The lowest scoring items (mean and median scores of 7.61 and 7.5, respectively, for both items) were “Endoscopic findings of purulence, edema, or polyps and involvement of >1 paranasal sinus may suggest the presence of secondary sinusitis with bacterial superinfection, obstructive rhinosinusitis or evolution towards invasive forms” and “Surgical treatment should be considered for asymptomatic PSFBs with suspected or ascertained secondary

CRS, although clinical and radiological follow-up represent an alternative in immunocompetent patients.”

4 | DISCUSSION

The multidisciplinary group of experts involved in the creation of the Delphi method consensus statement presented here delineated a specific all-around management guideline for PSFB, thereby covering a major gap in the literature.

High success rates in the treatment of PSFB have been reported (ie, 98.4% after surgery in a recent meta-analysis,² and 98.8% in the largest available case series⁷). The present CCS is unlikely to improve these figures. Rather, it aimed to contribute to streamlining the

TABLE 1 Statements and results from the Delphi process

Section	Item	Statement	Mean	Median	Range	Outliers	Final result
Definition	1a	PSFBs are per definition a noninvasive mycosis	7.84	9	1-9	1	Consensus (first Delphi round)
	1b	Although correlations with dental treatments and conditions have been described, maxillary PSFBs should not be routinely considered as odontogenic sinusitis cases, even if underlying dental pathology is identified	7.94	8	5-9	1	Consensus (second Delphi round)
Diagnosis	2a	PSFBs may become symptomatic and cause cacostmia, facial pain, nasal obstruction, or recurrent bleeding	7.84	8	5-9	1	Consensus (first Delphi round)
	2b	PSFBs may be diagnosed incidentally during other diagnostic workups without any accompanying symptoms	8.63	9	7-9	0	Strong consensus (first Delphi round)
	2c	Nasal endoscopy and at least 1 imaging exam (either CT or MRI) is mandatory in suspect PSFB workup	8.37	9	7-9	0	Strong consensus (first Delphi round)
	2d	PSFB may present with distinctive radiologic features such as hyperostotic changes in sinus walls, iron-like central cores, and sparse hyperdense sinus material at CT scans or T2 signal void at MRI scans	7.79	8	5-9	1	Consensus (first Delphi round)
	2e	PSFB radiologic workup can be completed with contrast medium CT or MRI scans if differential diagnosis with other unilateral paranasal sinus conditions or malignancies is required or for ruling out suspect bony erosion, soft tissue invasion, and/or cavernous sinus thrombosis	8	8	5-9	1	Consensus (second Delphi round)
	2f	Endoscopic findings of purulence, edema, or polyps and involvement of >1 paranasal sinus may suggest the presence of secondary sinusitis with bacterial superinfection, obstructive rhinosinusitis, or evolution toward invasive forms	7.61	7.5	5-9	1	Consensus (second Delphi round)
Treatment indications	3a	Treatment is recommended for symptomatic immunocompetent PSFBs and for asymptomatic PSFB patients in cases of immunodepression or planned immunosuppression	8.28	8.5	7-9	0	Strong consensus (second Delphi round)
	3b	Surgical treatment should be considered for asymptomatic PSFBs with suspected or ascertained secondary CRS, although clinical and radiologic follow-up represent an alternative in immunocompetent patients	7.61	7.5	6-9	1	Consensus (third Delphi round)

(Continues)

TABLE 1 (Continued)

Section	Item	Statement	Mean	Median	Range	Outliers	Final result
	3c	Maxillary PSFB treatment is mandatory before maxillary sinus augmentation procedures	8.37	9	6-9	1	Consensus (first Delphi round)
	3d	Maxillary PSFB treatment is recommended before dental implant placement in the upper jaw	7.95	9	4-9	1	Consensus (first Delphi round)
	3e	PSFB treatment is highly recommended in immunocompromised patients, especially in cases of secondary CRS	8.58	9	7-9	0	Strong consensus (first Delphi round)
	3f	PSFB treatment is highly recommended before iatrogenic immunosuppression (eg, transplant surgery), although such treatment can be delayed after starting urgent immunosuppressive treatments	7.78	8	5-9	1	Consensus (second Delphi round)
	3g	Watchful waiting could be considered when dealing with asymptomatic non-CRS PSFB patients, especially in high anesthesiologic risk comorbid and fragile patients, given proper counseling	8	8	7-9	0	Strong consensus (second Delphi round)
	3h	Patients with asymptomatic PSFB should be adequately counseled in balancing the risks of surgical treatment with those of watchful waiting, according to the single clinical scenario and to the location of the mycosis	7.95	8	4-9	1	Consensus (first Delphi round)
Surgical and medical treatment and follow-up	4a	PSFB treatment requires endoscopic sinus surgery, aimed at all involved sinuses identified via nasal endoscopy and/or imaging	8.53	9	5-9	1	Consensus (first Delphi round)
	4b	Complete removal of fungal hyphae improves the chances of treatment success and should be achieved through adequately sized accesses to the affected sinuses and may be facilitated by intraoperative sinus lavages	8.44	9	7-9	0	Strong consensus (second Delphi round)
	4c	In cases of clinical scenarios highly suggestive for PSFB hyphal material, biopsy alone confirms the diagnosis, while mucosal biopsies are required only to rule out invasive forms or for differential diagnosis or research purposes	7.89	8	7-9	1	Consensus (third Delphi round)
	4d	Antifungal therapy should not be prescribed in PSFB treatment, either pre- or postoperatively, except in cases of confirmed mucosal invasion or bony erosion with soft tissue invasion	8.28	8.5	7-9	0	Strong consensus (second Delphi round)
	4e	Empiric postoperative antibiotic treatment can be employed in PSFB presenting with polyps, edema, crusting, or purulent discharge and bacterial cultures, and antibiograms are encouraged in cases of suspected secondary CRS or bacterial superinfection	7.89	8	3-9	1	Consensus (second Delphi round)

(Continues)

TABLE 1 (Continued)

Section	Item	Statement	Mean	Median	Range	Outliers	Final result
	4f	When postoperative endoscopy demonstrates a widely patent ostia with a normal endoscopic examination, no strict follow-up is required, although a 6- to 24-month postoperative endoscopy is desirable in all patients, and a yearly endoscopy may allow early identification of recurrence and secondary sinus ostia closure in high-risk or immunosuppressed patients	7.78	8	5-9	1	Consensus (third Delphi round)
	4g	Postoperative imaging in PSFB should be limited to cases of possible or ascertained recurrence or complication or in patients where a full endoscopic evaluation of the originally affected sinuses is not allowed by anatomic or postsurgical features	7.83	8	5-9	1	Consensus (second Delphi round)

CRS = chronic rhinosinusitis; CT = computed tomography; MRI = magnetic resonance imaging; PSFB = paranasal sinus fungal balls.

diagnosis and therapeutic process, with a particular focus on unusual/uncommon clinical situations not covered by the available literature. This means improving the overall standard of care for patients and offering guidance to general otolaryngologists when managing difficult cases or to allied specialties in referring patients for rhinologic evaluation. The overall need for standardizing PSFB care emerges from the almost-constant presence of outlier results among our specialist-evaluated 23 consensus statements, even in sections on the definition of disease.

It should be noted that most reports in the literature suggest that PSFB treatment is solely surgical, and that medical treatments (especially antifungals) should not be considered a first-line option and their use should be employed only in specific cases, which are detailed in the CCS.

In terms of disease definition, the CCS confirmed the use of the DeShazo et al classification,⁸ as well as the non-routine inclusion of PSFB among odontogenic sinusitis cases, as suggested by Craig et al.⁹ Odontogenic sinusitis cases, whether or not presenting with maxillary PSFB, may be better defined according to different existing consensus documents.⁹

From our CCS, it has emerged that the existence of both symptomatic PSFB (ie, presenting with cacosmia, facial pain, nasal obstruction, or recurrent bleeding) and asymptomatic/incidentally found PSFB is widely accepted. Symptoms are important in the evaluation and management of patients, but they are not required for nosographic purposes, unlike a CRS diagnosis.⁴ It was also accepted that nasal endoscopy should be considered as a minimum standard in the diagnosis of PSFB, together with at least 1 computed tomography (CT) scan or magnetic resonance image (MRI). It was also accepted that nasal

endoscopy should be regarded as a minimum standard in PSFB diagnosis, coupled with at least 1 CT or MRI. Typical CT findings (an iron-like core; ie, foci of calcific deposits mimicking a metallic foreign body inside the sinus—or surrounding bone hyperostosis) and MR characteristics (T2 signal void) strengthen a PSFB diagnosis and do not require administration of contrast medium. The latter should be reserved for evaluating differential diagnoses or invasive behaviors that have been occasionally described.¹⁰ A more disputed issue, although reaching consensus, was delineating the role of PSFB accompanied by endoscopic findings of purulence, edema, or polyps and involvement of more than 1 paranasal, which were deemed signs of secondary sinusitis with bacterial superinfection, obstructive rhinosinusitis, or evolution toward invasive forms, as the literature indicates that PSFB should not be characterized by purulence or bacterial superinfection per se.¹¹ Literature reports suggest that bacterial superinfection may characterize more symptomatic cases, as well as all cases of PSFB with underlying odontogenic sinusitis.^{12,13}

Indications for treatment in standard and specific cases are the most important result of this CCS, as the literature to date has not covered these scenarios in a comprehensive manner. Nevertheless, such cases are commonplace in clinical practice. The basic assumption is that PSFB does not necessarily require treatment per se, and its management should be integrated with specific patient characteristics. The CCS concluded that the benefit/risk balance in PSFB favors treatment in some specific cases, yet other patients may choose watchful waiting, given appropriate counseling. Therefore, PSFB treatment is favored in the following cases: before maxillary sinus augmentation procedures (ie, procedures aimed to increase the posterior

maxilla vertical bone height placing a bone graft under the sinus mucosa allowing for dental implant placement—mandatory PSFB treatment); before planned iatrogenic immunosuppression or in immunocompromised patients (highly recommended, more even so if secondary rhinosinusitis develops); in symptomatic immunocompetent patients (recommended); and before upper jaw implant positioning (recommended). On the other hand, watchful waiting with adequate clinical and radiologic follow-up was considered an appropriate option to be offered to selected patients in cases of asymptomatic PSFB with normal immunocompetence and no secondary rhinosinusitis, especially in patients with high comorbidity and relevant anesthetic risk. Finally, immunocompetent patients showing PSFB with signs of secondary rhinosinusitis represent something of a middle ground, where surgery represents the best option. Nevertheless, careful follow-up should be undertaken.

Not surprisingly, ESS aimed at all involved sinuses was considered the only treatment option for PSFB in this CCS, with lavages and appropriate access used to completely remove the hyphal material. The CCS suggests limiting the use of antifungal therapy to cases with confirmed mucosal or soft tissue invasion (ie, when PSFB is not present, by definition) and employing antimicrobial therapy (possibly culture-driven) in cases with suspected bacterial superinfection of concomitant secondary rhinosinusitis. Mucosal biopsies, which some authors advocate in all PSFB cases,^{14,15} were deemed helpful in ruling out suspected invasive forms or other differential diagnoses, or for research purposes, whereas evidence of hyphal material was considered sufficient in highly suggestive PSFB scenarios, thus streamlining the diagnostic process.

Postoperative follow-up was the most debated single feature of PSFB management, due to the extremely low level of evidence. Ultimately, the CCS determined it reasonable that normal postoperative endoscopy findings with widely patent ostia were sufficient to end patient follow-up, suggesting a 6- to 24-month follow-up in high-risk patients (defined as immunocompromised, multimorbid, or incomplete hyphae excision) for early recurrence detection. Furthermore, the panelists suggested that follow-up should rely primarily on nasal endoscopy, limiting the use of postoperative imaging only to suspect recurrences, or in patients in whom unfavorable anatomy or postsurgical features hinder the full exploration of previously affected sinuses.

Although these general management indications are not meant to revolutionize PSFB treatment, it is our firm conviction that they can assist in streamlining the patient care process, balancing the risks and benefits of treatment vs watchful waiting, and optimizing resource allocation.

The results of this CCS are limited by the low overall quality of the currently available scientific evidence on this topic, which is based mostly on retrospectively collected data. The currently available literature, as circulated among CCS participants from the systematic review, is detailed in Supporting Information 3, which also reports the clinical study type, the evidence level according to the Oxford Centre for Evidence-Based Medicine (OCEBM) level of evidence guide,¹⁶ and the size of the patient pool for each article.

There is an inherent need for prospective studies covering the more widely debated areas of PSFB emerging from this consensus, such as postoperative follow-up duration and the treatment of bacterial superinfections. The first issue is related to the cost-effectiveness of the protocols, such as avoiding unnecessary consultations with specialists, while the second issue could reduce recurrences to zero and avoid overprescription of oral antibiotics, as has already been demonstrated extensively with ESS in other conditions.¹⁷ Among other areas of research and standardization, it is worth mentioning that our CCS does not provide guidance on the interval between PSFB treatment and initiation of immunosuppression, maxillary sinus augmentation procedures, or dental implant positioning. It may be safe to assume that complete postoperative healing with no residual crusting, or evidence of hyphal material or purulence, could greenlight immunosuppression or dental procedures; however, additional focused research is needed in this area. Furthermore, there is no consensus or literature guidance on the duration of follow-up in patients declining treatment or on the need for additional imaging in these patients. In this regard, patients' safety does not allow for suggestions to end follow-up, as local infection conditions may vary, even many years later, whereas imaging should be performed only when patients report worsening symptoms or the onset of new symptoms.

5 | CONCLUSION

Until further prospective studies on PSFB are available, this consensus statement suggests that PSFB is best managed following these main tenets. PSFB should be considered a noninvasive mycosis not necessarily related to odontogenic conditions or symptomatic. Although diagnosis may be incidental, endoscopy and 1 imaging examination (either CT or MRI, with distinctive features) are required for diagnosis, whereas contrast medium allows for differential diagnosis. PSFB treatment should be considered mandatory before maxillary sinus augmentation and is recommended for symptomatic patients; however, in immunocompromised patients, or patients with planned immunosuppression, watchful waiting could be

considered when dealing with asymptomatic, non-CRS patients who have been given proper counseling and evaluation.

ACKNOWLEDGMENT

Open Access funding provided by Università degli Studi di Milano.

[Correction added on 28 November 2022, after first online publication: CRUI funding statement has been added.]

CONFLICT OF INTEREST

The authors have no potential conflict of interest or financial disclosures pertaining to this article.

ORCID

Alberto Maria Saibene MD, MA  <https://orcid.org/0000-0003-1457-6871>

Fabiana Allevi MD, PhD  <https://orcid.org/0000-0002-5012-4031>

Christian Calvo-Henriquez MD  <https://orcid.org/0000-0003-3580-0967>

Nicolas Dauby MD, PhD  <https://orcid.org/0000-0002-7697-6849>


Rémi Hervochon MD, MSc  <https://orcid.org/0000-0003-1569-3578>

David Lobo-Duro MD, PhD  <https://orcid.org/0000-0002-4322-6638>

Luca Giovanni Locatello MD  <https://orcid.org/0000-0002-1879-5580>

Miguel Mayo-Yañez MD, MSc  <https://orcid.org/0000-0002-1829-6597>

Luigi Angelo Vaira MD  <https://orcid.org/0000-0002-7789-145X>

Leigh Sowerby MD, MHM, FRCSC  <https://orcid.org/0000-0002-5825-2759>

REFERENCES

- Kim YK, Kim HJ, Kim HY, et al. Extrasinonasal infiltrative process associated with a sinonasal fungus ball: does it mean invasive fungal sinusitis. *Diagn Interv Radiol*. 2016;22(4):347-353.
- Fadda GL, Allevi F, Rosso C, et al. Treatment of paranasal sinus fungus ball: a systematic review and meta-analysis. *Ann Otol Rhinol Laryngol*. 2021;130(11):1302-1310.
- Kim JS, So SS, Kwon SH. The increasing incidence of paranasal sinus fungus ball: a retrospective cohort study in two hundred forty-five patients for fifteen years. *Clin Otolaryngol*. 2017;42(1):175-179.
- Fokkens WJ, Lund VJ, Hopkins C, et al. European position paper on rhinosinusitis and nasal polyps 2020. *Rhinology*. 2020;58(S29):1-464.

- Rosenfeld RM, Nnacheta LC, Corrigan MD. Clinical consensus statement development manual. *Otolaryngol Head Neck Surg*. 2015;153:S1-S14.
- Page MJ, McKenzie JE, Bossuyt PM, et al. The PRISMA 2020 statement: an updated guideline for reporting systematic reviews. *Rev Esp Cardiol*. 2021;74(9):790-799.
- Liu X, Liu C, Wei H, et al. A retrospective analysis of 1,717 paranasal sinus fungus ball cases from 2008 to 2017. *Laryngoscope*. 2020;130(1):75-79.
- deShazo RD, O'Brien M, Chapin K, Soto-Aguilar M, Gardner L, Swain R. A new classification and diagnostic criteria for invasive fungal sinusitis. *Arch Otolaryngol Head Neck Surg*. 1997;123(11):1181-1188.
- Craig JR, Poetker DM, Aksoy U, et al. Diagnosing odontogenic sinusitis: an international multidisciplinary consensus statement. *Int Forum Allergy Rhinol*. 2021;11(8):1235-1248.
- Assiri AM, Ryu S, Kim JH. Concurrent diagnosis of sinus fungus ball and invasive fungal sinusitis: a retrospective case series. *Mycoses*. 2021;64(9):1117-1123.
- Fadda GL, Succo G, Moretto P, et al. Endoscopic endonasal surgery for sinus fungus balls: clinical, radiological, histopathological, and microbiological analysis of 40 cases and review of the literature. *Iran J Otorhinolaryngol*. 2019;31(102):35-44.
- Bulfamante AM, Pipolo C, D'Agostino Fiorenza U, et al. Spontaneous healing in maxillary fungus ball: beware of asymptomatic patients. *Clin Case Rep*. 2021;9(4):1865-1869.
- Saibene AM, Vassena C, Pipolo C, et al. Odontogenic and rhinogenic chronic sinusitis: a modern microbiological comparison. *Int Forum Allergy Rhinol*. 2016;6(1):41-45.
- Nicolai P, Lombardi D, Tomenzoli D, et al. Fungus ball of the paranasal sinuses: experience in 160 patients treated with endoscopic surgery. *Laryngoscope*. 2009;119(11):2275-2279.
- Castelnuovo P, Gera R, Di Giulio G, et al. Paranasal sinus mycoses. *Acta Otorhinolaryngol Ital*. 2000;20(1):6-15.
- Centre for Evidence-Based Medicine. OCEBM levels of evidence. Accessed: January 3, 2022. Available at: <https://www.cebm.ox.ac.uk/resources/levels-of-evidence/ocebml-levels-of-evidence>
- Lehmann AE, Raquib AR, Siddiqi SH, et al. Prophylactic antibiotics after endoscopic sinus surgery for chronic rhinosinusitis: a randomized, double-blind, placebo-controlled noninferiority clinical trial. *Int Forum Allergy Rhinol*. 2021;11(7):1047-1055.

SUPPORTING INFORMATION

Additional supporting information can be found online in the Supporting Information section at the end of this article.

How to cite this article: Saibene AM, Allevi F, Calvo-Henriquez C, et al. Comprehensive management of paranasal sinus fungus balls: A Young-IFOS consensus statement. *Int Forum Allergy Rhinol*. 2023;13:877-885. <https://doi.org/10.1002/alr.23093>