

# Immediate and short-term radiological changes after combining static stretching and transcutaneous electrical stimulation in adults with cavus foot

## A randomized controlled trial

Lourdes María Fernández-Seguín, PhD<sup>a</sup>, Alberto Marcos Heredia-Rizo, PhD<sup>a,\*</sup>, Juan Antonio Díaz-Mancha, PhD<sup>a</sup>, Paula González-García, PhD<sup>a</sup>, Javier Ramos-Ortega, PhD<sup>b</sup>, Pedro V. Munuera-Martínez, PhD<sup>b</sup>

### Abstract

**Background:** Cavus foot is a deformity represented by an increased and rigid medial longitudinal arch, and it is often associated with persistent pain and gait disturbances. None of the conservative conventional treatments for cavus foot have shown conclusive evidence of effectiveness, and so further is research needed to understand how to manage this condition better. This study aimed to assess the immediate and short-term radiological changes after combining static stretching and transcutaneous electrical stimulation of the plantar fascia in adults with idiopathic cavus foot.

**Methods:** A randomized, single-blinded clinical trial was conducted. Sixty-eight participants with idiopathic cavus foot, as determined by an internal Moreau–Costa–Bertani angle (MCBA) less than 125° in a lateral weight-bearing foot radiograph, were equally distributed into a neuromuscular stretching group (NSG) or a control group (no intervention). The NSG underwent a single session, combining transcutaneous electrical nerve stimulation with static stretching of the plantar fascia. Primary measurements of 3 angles were taken using a lateral weight-bearing foot radiograph: the internal MCBA; the calcaneal pitch angle (CPA); and the first metatarsal declination angle (FMDA). Outcomes were collected at baseline, immediately postintervention, and 1 week after intervention.

**Results:** Analysis of variance revealed a significant group effect for all angles (all,  $P < .05$ ). NSG participants showed a significant increase in the internal MCBA ( $P = .03$ ), and a significant decrease in the CPA ( $P = .01$ ) and FMDA ( $P = .04$ ) from baseline to immediately postintervention. These changes remained statistically significant 1 week after the intervention (all,  $P < .05$ ).

**Conclusion:** The combination of static stretching and transcutaneous electrical stimulation of the plantar fascia, compared with no treatment, achieved immediate and short-term changes in the internal MCBA, the CPA, and the FMDA, which resulted in flattening the medial longitudinal plantar arch in adults with idiopathic cavus foot.

**Abbreviations:** ANOVA = analysis of variance, CG = control group, CPA = calcaneal pitch angle, FMDA = first metatarsal declination angle, MCBA = Moreau–Costa–Bertani angle, NSG = neuromuscular stretching group.

**Keywords:** conservative treatment, foot deformity, physical therapy modality, radiology, transcutaneous electric nerve stimulation

Editor: Miao Liu.

The authors have no conflicts of interest to disclose.

<sup>a</sup>Department of Physiotherapy, <sup>b</sup>Department of Podiatry, Faculty of Nursing, Physiotherapy and Podiatry, University of Seville, Seville, Spain.

\* Correspondence: Alberto Marcos Heredia-Rizo, Departamento de Fisioterapia. Facultad de Enfermería, Fisioterapia y Podología, Universidad de Sevilla, España. c/ Avicena s/n, 41009 Sevilla, Spain (e-mail: amheredia@us.es).

Copyright © 2019 the Author(s). Published by Wolters Kluwer Health, Inc. This is an open access article distributed under the terms of the Creative Commons Attribution-Non Commercial License 4.0 (CCBY-NC), where it is permissible to download, share, remix, transform, and buildup the work provided it is properly cited. The work cannot be used commercially without permission from the journal.

How to cite this article: Fernández-Seguín LM, Heredia-Rizo AM, Díaz-Mancha JA, González-García P, Ramos-Ortega J, Munuera-Martínez PV. Immediate and short-term radiological changes after combining static stretching and transcutaneous electrical stimulation in adults with cavus foot. *Medicine* 2019;98:46(e18018).

Received: 26 February 2019 / Received in final form: 11 October 2019 / Accepted: 16 October 2019

<http://dx.doi.org/10.1097/MD.00000000000018018>

## 1. Introduction

Cavus foot, or pes cavus, is a structural foot deformity characterized by a high and rigid medial longitudinal arch,<sup>[1]</sup> frequently as a result of muscle imbalance,<sup>[2]</sup> and occurs bilaterally in approximately 10% to 15% of the population.<sup>[3]</sup> Around 60% of individuals with cavus foot are likely to report persistent foot pain due to high plantar pressures,<sup>[4,5]</sup> with a remarkably increased load under the metatarsal area.<sup>[6]</sup> Hence, foot pain related to cavus foot may lead to important functional limitations.<sup>[7]</sup>

Cavus foot can be classified into 3 main types: cavovarus foot (the most frequent type), calcaneovarus foot, and “pure” cavus foot.<sup>[1]</sup> While it can have a congenital, neurological, or traumatic origin,<sup>[5]</sup> the prevalence of cavus foot without an identifiable underlying deficit has steadily increased in recent years,<sup>[8]</sup> because the mechanisms underlying this foot deformity are not fully understood.<sup>[1]</sup> All presentations frequently provoke gait disturbances,<sup>[1]</sup> and result in a rigid plantarflexed position of the

forefoot on the rearfoot.<sup>[9]</sup> Therapeutic approaches for cavus foot, whether conservative or surgical, aim to decrease the plantarflexed position of the forefoot and relax the plantar fascia.<sup>[10–12]</sup> Lateral weight-bearing foot radiographs are used to measure the height of the plantar arch and represent an objective tool to assess treatment outcomes.<sup>[10,13]</sup>

Among nonoperative procedures, the use of orthoses, usually custom-made insoles,<sup>[14]</sup> is the most common strategy in the clinical setting to improve the distribution of the plantar pressures, provide comfort and stability during gait, and relieve fatigue in the lower extremities.<sup>[14–16]</sup> Additionally, various footwear models,<sup>[17]</sup> or intramuscular injections of botulinum toxin,<sup>[18]</sup> have been used to prevent progression of cavus foot and related disability. However, none of these treatments have conclusive scientific evidence of effectiveness, and there is a need for high-quality research to determine the efficacy of other approaches for cavus foot.<sup>[11]</sup>

Several physical modalities can be combined to manage foot disorders.<sup>[19]</sup> Manual therapy, joint range-of-motion exercises, stretching, and electrotherapy, are among the physical therapy interventions used to prevent or treat cavus foot,<sup>[11]</sup> with emphasis on maintaining the foot flexibility and reeducating the gait.<sup>[20]</sup> Stretching exercises are used to improve flexibility of the shortened muscles and thereby enhance functionality.<sup>[21,22]</sup> Combined electrical currents and stretching, referred to as electrical muscle elongation, is thought to facilitate gliding capacity of the deep connective tissue, allowing higher muscle flexibility,<sup>[23]</sup> although this remains controversial.<sup>[24–28]</sup>

To the best of the authors' knowledge, no previous study has evaluated the clinical impact of combining stretching and electrical currents in adults with cavus foot. Therefore, this study assessed the immediate and short-term radiological changes after combining electrical stimulation and static stretching of the plantar fascia in adults with idiopathic cavus foot. It was hypothesized that electrical elongation of the plantar fascia could flatten the medial longitudinal plantar arch, as assessed by changes in several radiological angles.

## 2. Methods

### 2.1. Study design

A single-blinded randomized, controlled clinical trial was undertaken. The updated guidelines of the consolidated standards of reporting trials for reporting parallel group randomized trials were followed.<sup>[29]</sup> All participants were informed of the general aspects of the study (possible benefits, risks, side-effects, and that it would compare different interventions). Participants and the evaluator who collected the outcome measures, remained unaware of the participants' allocation group to ensure participant and outcome assessor blinding.<sup>[30]</sup> Due to the nature of the trial, it was not possible to blind the therapist in charge of the intervention. An independent researcher used Microsoft Excel's randomization function to complete the randomization schedule for treatment order, taking into consideration a 1:1 ratio distribution of participants in the study groups: the neuromuscular stretching group (NSG), and the control group (CG). An external assistant, not involved in the clinical trial, safeguarded the randomization sequence, and sealed, opaque envelopes were used to conceal the treatment order allocation.

The study was conducted in accordance with the Helsinki Declaration and approved by the Institutional Review Board

(project code: 17-F-08). The protocol was prospectively registered in the Brazilian Register of Clinical Trials (UTN number: U1111-1207-0161). All participants provided verbal and written informed consent.

### 2.2. Participants

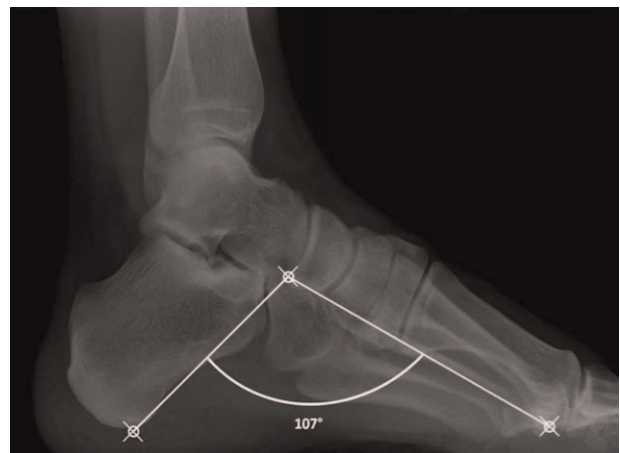Based on a nonprobabilistic convenience sampling, 74 adults, who volunteered to participate, were consecutively recruited at the podiatric clinic at a large public university in southern Spain. To be eligible, participants had to be aged 18 to 45 years, and with a diagnosis of idiopathic cavus foot. Those participants with an internal Moreau–Costa–Bertani angle (MCBA) less than 125° in a lateral weight-bearing foot radiograph were included (Fig. 1).<sup>[31]</sup> The exclusion criteria were as follows: a diagnosis of degenerative, musculoskeletal, tumoral, or systemic disease; a history of foot or lower extremity surgery<sup>[6]</sup>; having received manual treatment in the lower legs in the 4 weeks before data collection; current use of orthopodiatric treatment for cavus foot; consumption of analgesics or anti-inflammatory drugs within 48 hours before the study; previous severe traumas or fractures affecting the lower extremities; and reporting current or recurring pain in the lower extremity that could interfere with standing position.<sup>[32]</sup>

### 2.3. Study protocol

Following randomization, clinical and demographic data were initially collected. At baseline, a lateral weight-bearing foot radiograph was taken, and 3 different angles were measured. Between 3 and 7 days after baseline, the intervention was performed in both study groups by a physiotherapist with more than 10 years of clinical experience. The second evaluation was carried out immediately postintervention, and the last session took place 1 week after the intervention. A single examiner assessed all outcome measures.

### 2.4. Measurements

A lateral weight-bearing foot radiograph was acquired using a portable X-ray device operating at 45 kV and 4 mA/s (Sedecal SPS HF-4.0; Sedecal, Madrid, Spain). Radiographs were taken from



**Figure 1.** Radiological assessment of the internal Moreau–Costa–Bertani angle.

the dominant foot in all participants, keeping a 1-m distance between the X-ray device and the foot. Three different angles were measured using the AutoCAD software package, version 20.0 (AutoDesk, San Rafael, CA):

- (1) the internal MCBA, which is defined by the line originating from the lower pole of the medial sesamoid bone and the line originating from the lowest point of the posterior calcaneal tuberosity, both joining at the lower point of the talonavicular joint.<sup>[33]</sup> This angle is considered as an appropriate measure of the medial longitudinal plantar arch,<sup>[33]</sup> and its normal value is around  $125^\circ$  [31];
- (2) the calcaneal pitch angle (CPA), represented by the angle between the inferior surface of the calcaneus and the supporting surface, with a normal value of  $20^\circ$  (Fig. 2A).<sup>[34]</sup> The CPA is a valid assessment tool,<sup>[35]</sup> with a high intra- and inter-observer reliability,<sup>[36]</sup> and represents the preferred radiological angle to diagnose cavus foot<sup>[37]</sup>; and
- (3) the first metatarsal declination angle (FMDA), measured as the angle between the axis of the first metatarsal shaft and the supporting surface, with a normal value of  $20^\circ$  (Fig. 2B).<sup>[38]</sup>

## 2.5. Interventions

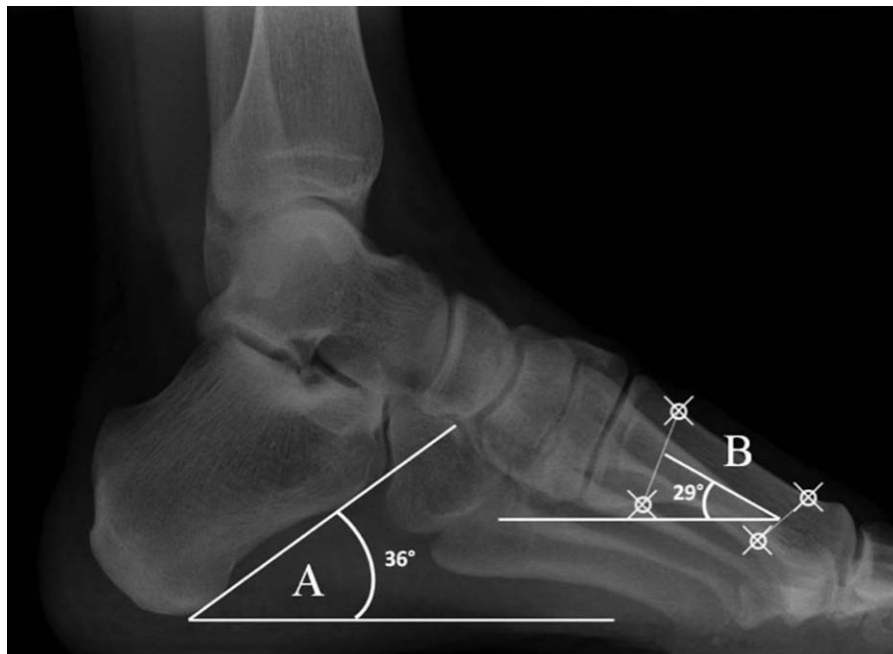The NSG participants underwent a neuromuscular stretching technique of the plantar fascia using transcutaneous electrical nerve stimulation with symmetric rectangular biphasic current (TENS MED 931; Enraf–Nonius, Rotterdam, Netherlands). A 50-Hz pulse frequency, with a 300- $\mu$ s pulse width was used. Two rubber electrodes were fitted into sponges of equal size. One electrode ( $10 \times 5$  cm) was placed at the retrocapital metatarsal area, and the other electrode ( $5 \times 5$ ) was located over the heel. The participant stood on 1 leg and held onto a bar to maintain balance. First, the plantar muscles were placed in a stretched

position. Then, the current intensity was set at the participant's maximal tolerance to achieve a strong and comfortable tingling, but without evoking visible muscle twitches.<sup>[24]</sup> As the participants started to accommodate the current intensity, the therapist increased the intensity to reach the maximal tolerance threshold. This procedure was repeated 3 times, in line with previous research using post-isometric muscle relaxation techniques.<sup>[39,40]</sup> The whole intervention protocol lasted between 8 and 10 minutes. Meanwhile, the CG participants received no intervention but waited in a standing position for 10 minutes before the post-intervention assessment started.

## 2.6. Statistical analysis

Based on a previous pilot study, and assuming a 1-tailed hypothesis, a between-group allocation ratio of 1:1, a medium effect size ( $d=0.55$ ), an alpha value of 0.05, and a desired power of 90% (G\*Power 3.1.2; Kiel University, Kiel, Germany), 30 participants per group were necessary to complete the study. To account for potential dropouts, 34 adults were finally included in each group.

Statistical analysis was performed using the PASW Advanced Statistics (version 23.0; SPSS, Inc, Chicago, IL). Data are reported as mean and standard deviation. Normal distribution of study variables was assessed using the Shapiro–Wilk test. To check the intra-rater reliability of the assessment procedure, 10 radiographs were randomly chosen, and the internal MCBA, the CPA, and the FMDA were measured twice, with 10 days between measurements. The intra-class correlation coefficient was calculated using the data obtained from these measurements.<sup>[41]</sup> A repeated-measures analysis of variance (ANOVA) was applied to assess changes in the radiological angles from baseline to immediately postintervention and 1 week after intervention. Bonferroni adjustment for post hoc pairwise comparisons was used. Mixed-model ANOVAs were used to compare the differences



**Figure 2.** Radiological assessment of the calcaneal pitch angle (A), and the first metatarsal declination angle (B).

in the mean radiological changes following intervention between groups. Values of Pearson product–moment correlation coefficient analysis indicated the associations between the radiological angles. Statistical significance was set at  $P < .05$ .

**3. Results**

Sixty-eight participants (42 females, 61.8%), aged 19 to 37 years ( $24.2 \pm 5.2$ ), met the eligibility criteria and were finally included and equally distributed between the study groups. There were no adverse reactions or dropouts during the study protocol (Fig. 3). The intra-class correlation coefficient values for the internal MCBA, the CPA, and the FMDA were 0.972, 0.981, and 0.941, respectively. These results are similar to those of previous studies,<sup>[41,42]</sup> and suggest good reproducibility of the measurements.

Table 1 includes the baseline characteristics of the participants. At baseline, there were no differences between groups in any study variable (all,  $P > .05$ ). Table 2 lists the radiological angles measured at the different assessment points (baseline, immediately postintervention, and 1 week after intervention) in both

study groups. In the NSG, ANOVA showed a significant increase for the internal MCBA ( $P = .03$ ), and a significant decrease for the CPA ( $P = .01$ ) and the FMDA ( $P = .04$ ) when comparing assessments at baseline and immediately postintervention. These changes remained statistically significant 1 week after intervention (all,  $P < .05$ ). In the between-group comparison of the mean changes after intervention, ANOVAs revealed a statistically significant group effect for all angles (all,  $P < .05$ ), except for the CPA when comparing findings at baseline and 1 week after intervention ( $P = .445$ ) (Fig. 4).

For the correlation analysis, the internal MCBA had a significant negative correlation with the CPA ( $r = -0.651$ ,  $P < .001$ ) the FMDA ( $r = -0.772$ ,  $P < .001$ ), respectively.

**4. Discussion**

The present findings demonstrated that combining transcutaneous electrical nerve stimulation with static stretching of the plantar fascia, compared with no treatment, achieved immediate and short-term radiological changes in adults with idiopathic cavus foot. These changes represented a flattening of the medial

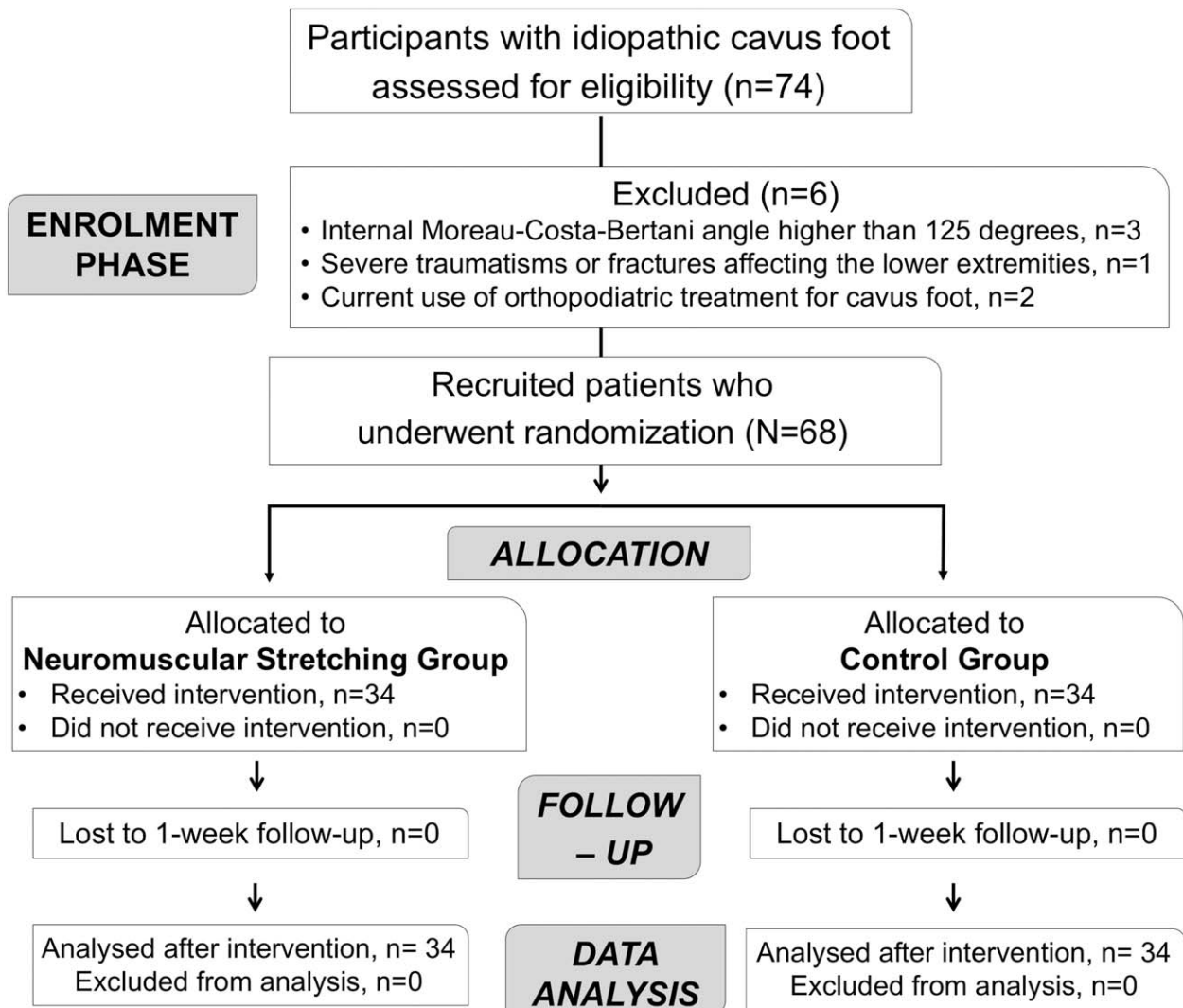


Figure 3. CONSORT flowchart of study participants. CONSORT = consolidated standards of reporting trials.

**Table 1**  
**Baseline characteristics of participants in the study groups, mean ± standard deviation, or (frequency percentages).**

	NS group (n = 34)	Control group (n = 34)	P-value
Mean age, yr	22.2 ± 5.2	26 ± 6	.95
Sex (female) % (n)	61.8% (21)	61.8% (21)	1.00
Height, cm	169.79 ± 9.18	169.21 ± 8.87	.98
Weight, kg	64.41 ± 13.74	70.17 ± 3.22	.13
Body mass index, kg/m <sup>2</sup>	22.11 ± 2.64	24.11 ± 1.98	.13
Internal Moreau–Costa–Bertani angle, °	113.21 ± 6.48	114.22 ± 5.45	.36
Calcaneal pitch angle, °	27.73 ± 4.40	27.84 ± 4.36	.89
First metatarsal declination angle, °	26.06 ± 3.63	25.34 ± 4.86	.25

NS = neuromuscular stretching.

longitudinal foot arch, with an increase of the internal MCBA, and a decrease of the CPA and the FMDA.

It is suggested that successful treatment for cavus foot should modify the increased medial longitudinal plantar arch, and achieve a painless, plantigrade, shoe-able foot.<sup>[15]</sup> Conservative treatments, such as orthoses and stretching protocols, are recommended for those with a mild cavus deformity.<sup>[22,43]</sup> Previous research has evaluated the efficacy of combining electrical currents with stretching exercises in different populations, with conflicting evidence. The use of transcutaneous electrical nerve stimulation during static stretching is purported to enhance stretch tolerance, leading to increased flexibility and range of movement, as evidenced in physically-active adolescents after an 8-week intervention program,<sup>[25]</sup> and in healthy young males,<sup>[26]</sup> and adults,<sup>[44]</sup> after a single treatment session. Previous findings also concluded that adding electrical stimulation to stretching might be highly effective in decreasing pain and muscle hardness in a healthy population,<sup>[26]</sup> and modify the plantar pressure in patients with idiopathic cavus foot.<sup>[11]</sup> However, contrarily, the concurrent use of transcutaneous electrical nerve stimulation, interferential currents, or neuromuscular electrical stimulation with stretching did not benefit muscle flexibility, range-of-motion, or function, compared with stretching alone, in healthy adults,<sup>[24]</sup> athletes,<sup>[27]</sup> young women,<sup>[45]</sup> and post-stroke patients.<sup>[46,47]</sup> To date, this is the first study to use electrical muscle elongation as a treatment for idiopathic cavus foot. We aimed to observe the changes in foot radiological angles after intervention, instead of assessing improvements in flexibility or

range of movement, as most former research has done.<sup>[24,25,27,44,46,47]</sup> Besides, previous studies applied the electrical stimulation predominantly over the hamstring muscles,<sup>[25–27,44]</sup> or the calf area,<sup>[24]</sup> but not in the plantar fascia. Finally, although we chose the electrical current parameters based on the best available evidence,<sup>[48]</sup> differences in the type of electrical current, the current parameters, the number of sessions, and treatment duration may account for these inconsistencies among studies and make it difficult to compare results. It is; therefore, not possible to reach a definitive conclusion about the clinical benefits of combining electrical stimulation with stretching interventions, because most studies in this field, except for de Jong et al,<sup>[46]</sup> and Leung et al,<sup>[47]</sup> have only assessed healthy participants.

Similar to the current results, the use of custom-made orthoses helps to flatten the foot arch in individuals with bilateral cavus foot, with a mean decrease of 3° for the CPA.<sup>[13]</sup> Contrary to this, recent studies have observed a slight increase of between 2.0° and 2.5° in the CPA following invasive interventions with potential side effects, for instance, arthroscopic resection or triple arthrodesis.<sup>[49,50]</sup> Changes in the CPA are likely to benefit the treatment and prevention of cavus foot.<sup>[13,51]</sup> In our study, the NSG participants demonstrated a considerable decrease in the CPA immediately postintervention (1.14°), and 1 week after intervention (0.91°). Even though the changes in the CPA were smaller than those reported by Eslami et al,<sup>[13]</sup> these results were achieved after a single intervention session. This finding infers that the repeated use of neuromuscular stretching of the plantar fascia might help to maintain these changes in the medium- and long-term, but remains speculative. The value of the internal MCBA was negatively correlated with the CPA and the FMDA. Therefore, the observed decrease in the CPA and the FMDA could also explain the increase in the internal MCBA after intervention and, consequently, the flattening of the medial longitudinal foot arch. However, various and inconsistent clinical measures of static foot posture exist, which should be considered when comparing among studies.<sup>[52]</sup>

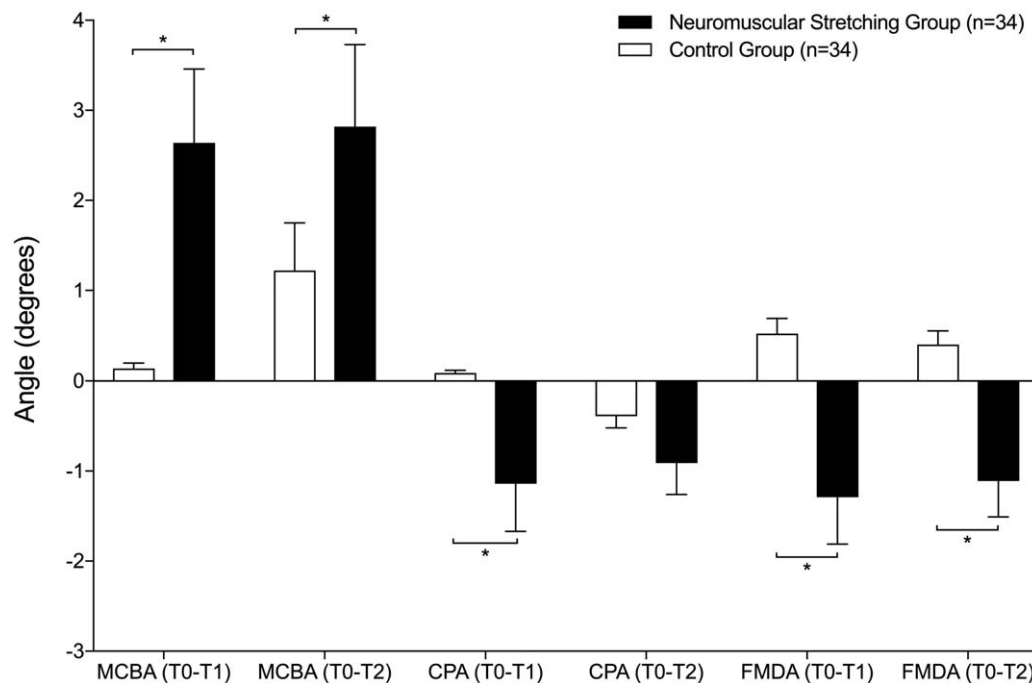
Metatarsal pain is a common related symptom in individuals with cavus foot, and it is often associated with plantar fasciitis and sesamoiditis.<sup>[16,53]</sup> Compared with neutral feet, those with cavus foot show greater pressure under the forefoot,<sup>[6]</sup> which could be attributed, in part, to a greater inclination of the metatarsal bones relative to the ground. The use of cavus foot orthoses effectively decreases pain and ankle instability.<sup>[54]</sup> Consequently, modifying the foot angles, such as the FMDA,

**Table 2**  
**Radiological angles values at different assessment points; mean ± standard deviation (95% confidence intervals).**

	Baseline	Immediately postintervention	One week after intervention
Internal Moreau–Costa–Bertani angle, °			
Neuromuscular stretching group	113.21 ± 6.48 (110.94–115.47)	115.85 ± 5.44* (113.96–117.75)	116.03 ± 4.32† (114.01–118.05)
Control group	114.22 ± 5.45 (112.38–116.06)	114.36 ± 6.36 (113.14–115.59)	115.47 ± 5.86 (113.04–117.89)
Calcaneal pitch angle, °			
Neuromuscular stretching group	27.73 ± 4.40 (26.21–29.27)	26.59 ± 4.28* (25.09–28.08)	26.82 ± 4.01† (25.23–28.41)
Control group	27.84 ± 4.36 (26.29–29.40)	27.93 ± 4.68 (26.03–29.84)	27.45 ± 4.28 (26.38–28.52)
First metatarsal declination angle, °			
Neuromuscular stretching group	26.06 ± 3.63 (24.79–27.32)	24.76 ± 3.04* (23.70–25.82)	24.95 ± 3.23† (23.94–25.96)
Control group	25.34 ± 4.86 (23.57–27.12)	25.86 ± 5.06 (23.72–27.98)	25.74 ± 5.25 (23.55–27.92)

\* Indicates significant differences in the pairwise comparison from baseline to immediately postintervention.

† Indicates significant differences in the pairwise comparison from baseline to 1 wk after intervention.



**Figure 4.** Pairwise comparison of the mean score changes from baseline to immediately postintervention (T0–T1), and from baseline to 1 wk after the intervention (T0–T2). CPA=calcaneal pitch angle, FMDA=first metatarsal declination angle, MCBA = internal Moreau–Costa–Bertani angle.

could help to relieve the associated symptoms and prevent functional impairments.

Some potential study limitations should be mentioned. First, this is a preliminary trial that assessed immediate and short-term (1 week after intervention) radiological changes, so the results should be interpreted carefully. Second, we recruited adults aged 18 to 45 years. Although debatable,<sup>[55]</sup> it is reported that the prevalence of cavus foot starts to decrease after the age of 50 years.<sup>[56]</sup> Therefore, it would be of interest to study the impact of electrical muscle elongation in an older population with cavus foot. Third, measurements were only made on the dominant foot after a single session. Fourth, the minimum clinically important difference between the assessed foot angles has not been calculated, and so the clinical relevance of these findings remains uncertain. Finally, the evaluation of related symptoms, such as foot pain, was beyond the scope of this study.

## 5. Conclusions

The combination of static stretching and transcutaneous electrical nerve stimulation has an immediate and short-term positive impact on the internal MCBA, the CPA, and the FMDA, compared with no treatment, and helps to flatten the longitudinal medial arch in adults with idiopathic cavus foot. Future research should assess the long-term adaptations of foot angles after neuromuscular stretching of the plantar fascia, and combine electrical muscle elongation with other therapeutic approaches, such as manual therapy and the use of orthoses, to reflect daily clinical practice.

## Author contributions

**Conceptualization:** Lourdes M. Fernández-Seguín, Alberto Marcos Heredia-Rizo, Javier Ramos-Ortega, Pedro V. Munuera-Martínez.

**Data curation:** Lourdes M. Fernández-Seguín, Alberto Marcos Heredia-Rizo, Juan Antonio Díaz-Mancha, Paula González-García.

**Formal analysis:** Lourdes M. Fernández-Seguín, Alberto Marcos Heredia-Rizo, Juan A. Díaz-Mancha, Paula González-García, Pedro V. Munuera-Martínez.

**Investigation:** Lourdes M. Fernández-Seguín, Juan A. Díaz-Mancha, Paula González-García, Javier Ramos-Ortega, Pedro V. Munuera-Martínez.

**Methodology:** Lourdes M. Fernández-Seguín, Alberto Marcos Heredia-Rizo, Javier Ramos-Ortega, Pedro V. Munuera-Martínez.

**Project administration:** Lourdes M. Fernández-Seguín, Pedro V. Munuera-Martínez.

**Resources:** Lourdes M. Fernández-Seguín, Javier Ramos-Ortega, Pedro V. Munuera-Martínez.

**Supervision:** Lourdes M. Fernández-Seguín, Pedro V. Munuera-Martínez.

**Visualization:** Lourdes M. Fernández-Seguín, Alberto Marcos Heredia-Rizo.

**Writing – original draft:** Lourdes M. Fernández-Seguín, Alberto Marcos Heredia-Rizo, Juan A. Díaz-Mancha, Paula González-García, Javier Ramos-Ortega, Pedro V. Munuera-Martínez.

**Writing – review and editing:** Lourdes M. Fernández-Seguín, Alberto Marcos Heredia-Rizo, Juan A. Díaz-Mancha, Paula González-García, Javier Ramos-Ortega, Pedro V. Munuera-Martínez.

Alberto Marcos Heredia-Rizo orcid: 0000-0003-2847-2846.

Pedro V. Munuera-Martínez orcid: 0000-0001-5708-4178.

## References

- [1] Burns J, Landorf KB, Ryan MM, et al. Interventions for the prevention and treatment of pes cavus. *Cochrane Database Syst Rev* 2007;4: CD006154.

- [2] Rosenbaum AJ, Lisella J, Patel N, et al. The cavus foot. *Med Clin North Am* 2014;98:301–12.
- [3] Walker M, Fan HJ. Relationship between foot pressure pattern and foot type. *Foot Ankle Int* 1998;19:379–83.
- [4] Burns J, Crosbie J, Ouvrier R, et al. Effective orthotic therapy for the painful cavus foot: a randomized controlled trial. *J Am Podiatr Med Assoc* 2006;96:205–11.
- [5] Burns J, Crosbie J, Hunt A, et al. The effect of pes cavus on foot pain and plantar pressure. *Clin Biomech (Bristol, Avon)* 2005;20:877–82.
- [6] Fernández-Seguín LM, Diaz Mancha JA, Sánchez Rodríguez R, et al. Comparison of plantar pressures and contact area between normal and cavus foot. *Gait Posture* 2014;39:789–92.
- [7] Badlissi F, Dunn JE, Link CL, et al. Foot musculoskeletal disorders, pain, and foot-related functional limitation in older persons. *J Am Geriatr Soc* 2005;53:1029–33.
- [8] Di Fabio R, Lispi L, Santorelli FM, et al. Idiopathic pes cavus in adults is not associated with neurophysiological impairment in the lower limbs. *Neurol Sci* 2015;36:2287–90.
- [9] Aminian A, Sangeorzan BJ. The anatomy of cavus foot deformity. *Foot Ankle Clin* 2008;13:191–8.
- [10] Singh AK, Briggs PJ. Metatarsal extension osteotomy without plantar aponeurosis release in cavus feet. The effect on claw toe deformity a radiographic assessment. *Foot Ankle Surg* 2012;18:210–2.
- [11] Fernández-Seguín LM, Munuera PV, Peña-Algaba C, et al. Effectiveness of neuromuscular stretching with symmetrical biphasic electric currents in the cavus foot. *J Am Podiatr Med Assoc* 2013;103:191–6.
- [12] Wicart P. Cavus foot, from neonates to adolescents. *Orthop Traumatol Surg Res* 2012;98:813–28.
- [13] Eslami M, Tanaka C, Hinse S, et al. Acute effect of orthoses on foot orientation and perceived comfort in individuals with pes cavus during standing. *Foot (Edinb)* 2009;19:1–6.
- [14] Choi JK, Cha EJ, Kim KA, et al. Effects of custom-made insoles on idiopathic pes cavus foot during walking. *Biomed Mater Eng* 2015;26 (Suppl 1):S705–15.
- [15] Solis G, Hennessy M, Saxby T. Pes cavus: a review. *Foot Ankle Surg* 2000;6:145–53.
- [16] Crosbie J, Burns J. Are in-shoe pressure characteristics in symptomatic idiopathic pes cavus related to the location of foot pain? *Gait Posture* 2008;27:16–22.
- [17] Wegener C, Burns J, Penkala S. Effect of neutral-cushioned running shoes on plantar pressure loading and comfort in athletes with cavus feet: a crossover randomized controlled trial. *Am J Sports Med* 2008;36:2139–46.
- [18] Burns J, Scheinberg A, Ryan MM, et al. Randomized trial of botulinum toxin to prevent pes cavus progression in pediatric Charcot-Marie-Tooth disease type 1A. *Muscle Nerve* 2010;42:262–7.
- [19] Helfand AE. Physical modalities in the management of mild to moderate foot pain. *Clin Podiatr Med Surg* 1994;11:107–23.
- [20] Nogueira MP, Farcetta F, Zuccon A. Cavus foot. *Foot Ankle Clin* 2015;20:645–56.
- [21] Batista LH, Vilar AC, de Almeida Ferreira JJ, et al. Active stretching improves flexibility, joint torque, and functional mobility in older women. *Am J Phys Med Rehabil* 2009;88:815–22.
- [22] Manoli A, Graham B. The subtle cavus foot, “the underpronator”. *Foot Ankle Int* 2005;26:256–63.
- [23] Maya J, Albornoz M. *Estimulación Eléctrica Transcutánea y Neuromuscular*. Barcelona (Spain): Elsevier; 2010.
- [24] Capobianco RA, Almklass AM, Enoka RM. Manipulation of sensory input can improve stretching outcomes. *Eur J Sport Sci* 2018;18:83–91.
- [25] Piqueras-Rodríguez F, Palazón-Bru A, Gil-Guillén VF. Effectiveness analysis of active stretching versus active stretching plus low-frequency electrical stimulation in children who play soccer and who have the short hamstring syndrome. *Clin J Sport Med* 2016;26:59–68.
- [26] Karasuno H, Ogihara H, Morishita K, et al. The combined effects of transcutaneous electrical nerve stimulation (TENS) and stretching on muscle hardness and pressure pain threshold. *J Phys Ther Sci* 2016;28:1124–30.
- [27] Espejo-Antunez L, Lopez-Miñarro P, Albornoz-Cabello M, et al. Acute effect of electrical muscle elongation and static stretching in hamstring muscle extensibility. *Sci Sports* 2016;31:1–7.
- [28] Mizuno T. Combined effects of static stretching and electrical stimulation on joint range of motion and muscle strength. *J Strength Cond Res* 2019;33:2694–703.
- [29] Schulz KF, Altman DG, Moher D, et al. CONSORT 2010 statement: updated guidelines for reporting parallel group randomised trials. *PLoS Med* 2010;7:e1000251.
- [30] Chess LE, Gagnier J. Risk of bias of randomized controlled trials published in orthopaedic journals. *BMC Med Res Methodol* 2013;13:76.
- [31] Etxebarria-Foronda I, Garmilla-Iglesias I, Gay-Vitoria I, et al. Surgical treatment of infantile flexible flail using the calcaneus-stop technique [Spanish]. *Gac Med Bilbao* 2006;103:149–53.
- [32] Buldt AK, Forghany S, Landorf KB, et al. Foot posture is associated with plantar pressure during gait: a comparison of normal, planus and cavus feet. *Gait Posture* 2018;62:235–40.
- [33] González Trujano A, Fuentes Nucamendi MA. Radiological evaluation of the flexibles pes planus treated with conic endorthesis [Spanish]. *Acta Ortop Mex* 2008;22:169–74.
- [34] Ledoux WR, Rohr ES, Ching RP, et al. Effect of foot shape on the three-dimensional position of foot bones. *J Orthop Res* 2006;24:2176–86.
- [35] Menz HB, Munteanu SE. Validity of 3 clinical techniques for the measurement of static foot posture in older people. *J Orthop Sports Phys Ther* 2005;35:479–86.
- [36] Sensiba PR, Coffey MJ, Williams NE, et al. Inter- and intraobserver reliability in the radiographic evaluation of adult flatfoot deformity. *Foot Ankle Int* 2010;31:141–5.
- [37] Akdoğan I, Akkaya S, Akkaya N, et al. Comparison of the calcaneal pitch angle and modified projection area per length squared method for medial longitudinal arch evaluation of the foot. *Balkan Med J* 2012;29:406–9.
- [38] Cicchinelli LD, Pascual Huerta J, García Carmona FJ, et al. Analysis of gastrocnemius recession and medial column procedures as adjuncts in arthroereisis for the correction of pediatric pes planovalgus: a radiographic retrospective study. *J Foot Ankle Surg* 2008;47:385–91.
- [39] Lewit K, Simons DG. Myofascial pain: relief by post-isometric relaxation. *Arch Phys Med Rehabil* 1984;65:452–6.
- [40] Parsons J, Mercer N. *Osteopathy*. Madrid (Spain): Elsevier Churchill Livingstone; 2007.
- [41] Távora-Vidalón SP, Monge-Vera M, Lafuente-Sotillos G, et al. Static range of motion of the first metatarsal in the sagittal and frontal planes. *J Clin Med* 2018;7:E456.
- [42] Munuera PV, Dominguez G, Polo J, et al. Medial deviation of the first metatarsal in incipient hallux valgus deformity. *Foot Ankle Int* 2006;27:1030–5.
- [43] Maynou C, Szymanski C, Thiounn A. The adult cavus foot. *EFORT Open Rev* 2017;2:221–9.
- [44] Song W, Seo H, Shin W. Effects of electric stimulation with static stretching on hamstrings flexibility. *J Kor Phys Ther* 2015;27:164–8.
- [45] Maciel A, Câmara S. Influence of transcutaneous electrical nerve stimulation (TENS) associate with muscle stretching on flexibility gains. *Rev Bras Fisiot* 2008;12:373–8.
- [46] de Jong LD, Dijkstra PU, Gerritsen J, et al. Combined arm stretch positioning and neuromuscular electrical stimulation during rehabilitation does not improve range of motion, shoulder pain or function in patients after stroke: a randomised trial. *J Physiother* 2013;59:245–54.
- [47] Leung J, Harvey LA, Moseley AM, et al. Electrical stimulation and splinting were not clearly more effective than splinting alone for contracture management after acquired brain injury: a randomised trial. *J Physiother* 2012;58:231–40.
- [48] Doucet BM, Lam A, Griffin L. Neuromuscular electrical stimulation for skeletal muscle function. *Yale J Biol Med* 2012;85:201–15.
- [49] Bourlez J, Joly-Monrignat P, Alkar F, et al. Does arthroscopic resection of a too-long anterior process improve static disorders of the foot in children and adolescents? *Int Orthop* 2018;42:1307–12.
- [50] Child BJ, Hix J, Catanzariti AR, et al. The effect of hindfoot realignment in triple arthrodesis. *J Foot Ankle Surg* 2009;48:285–93.
- [51] Subotnick SI. Foot orthoses: an update. *Phys Sports Med* 1983;11:103–9.
- [52] Langley B, Cramp M, Morrison SC. Clinical measures of static foot posture do not agree. *J Foot Ankle Res* 2016;9:45.
- [53] Schwend RM, Drennan JC. Cavus foot deformity in children. *J Am Acad Orthop Surg* 2003;11:201–11.
- [54] LoPiccolo M, Chilvers M, Graham B, et al. Effectiveness of the cavus foot orthosis. *J Surg Orthop Adv* 2010;19:166–9.
- [55] Troiano G, Nante N, Citarelli GL. Pes planus and pes cavus in Southern Italy: a 5 years study. *Ann Ist Super Sanita* 2017;53:142–5.
- [56] Atamturk D. Relationship of flatfoot and high arch with main anthropometric variables. *Acta Orthop Traumatol Turc* 2009;43:254–9.